

Diagnostic work-up of bile duct strictures: European Society of Gastrointestinal Endoscopy (ESGE) Guideline



Authors

Antonio Facciorusso^{1,2} , Stefano Francesco Crinò³, Paraskevas Gkolfakis⁴, Marco Spadaccini⁵, Marianna Arvanitakis⁶, Torsten Beyna⁷ , Michiel Bronswijk^{8,9} , Jahnvi Dhar¹⁰, Mark Ellrichmann¹¹ , Rodica Gincul¹², Istvan Hritz¹³, Leena Kylänpää¹⁴, Belen Martinez-Moreno¹⁵ , Martina Pezzullo¹⁶, Mihai Rimbaş^{17,18} , Jayanta Samanta¹⁰ , Roy L.J. van Wanrooij¹⁹ , George Webster²⁰, Konstantinos Triantafyllou²¹

Institutions

- 1 Experimental Medicine, Università del Salento, Lecce, Italy
- 2 Clinical Effectiveness Research Group, Institute of Health and Society, Faculty of Medicine, University of Oslo, Oslo, Norway
- 3 Gastroenterology, University of Verona, Verona, Italy
- 4 Gastroenterology, "Konstantopoulou-Patision" General Hospital of Nea Ionia, Athens, Greece
- 5 Endoscopy Unit, Istituto Clinico Humanitas, Rozzano, Italy
- 6 Gastroenterology, Digestive Oncology and Hepatopancreatology, HUB Hôpital Erasme, Brussels, Belgium
- 7 Internal Medicine, Evangelisches Krankenhaus Düsseldorf, Düsseldorf, Germany
- 8 Gastroenterology and Hepatology, Imelda Hospital, Bonheiden, Belgium
- 9 Gastroenterology and Hepatology, KU Leuven University Hospitals Leuven, Leuven, Belgium
- 10 Gastroenterology, PGIMER, Chandigarh, India
- 11 Interdisciplinary Endoscopy, Medical Department I, University Hospital Schleswig-Holstein, Campus Kiel, Kiel, Germany
- 12 Gastroenterology, Jean Mermoz Private Hospital, Lyon, France
- 13 Centre for Therapeutic Endoscopy, Semmelweis University, Budapest, Hungary
- 14 Surgery, Helsinki University Central Hospital, Helsinki, Finland
- 15 Endoscopy Unit, Hospital General Universitario de Alicante, Alicante, Spain
- 16 Radiology, Erasmus Hospital, Bruxelles, Belgium
- 17 Gastroenterology, Colentina Clinical Hospital, Bucharest, Romania
- 18 Internal Medicine Department, Carol Davila University of Medicine and Pharmacy, Bucharest, Romania

- 19 Gastroenterology and Hepatology, Amsterdam UMC Locatie VUmc, Amsterdam, Netherlands
- 20 Pancreatobiliary Medicine Unit, University College London, London, United Kingdom of Great Britain and Northern Ireland
- 21 Hepatogastroenterology Unit, 2nd Department of Internal Medicine, Propaedeutic, Medical School, National and Kapodistrian University of Athens, "Attikon" University General Hospital, Athens, Greece

published online 0.0.2024

Bibliography

Endoscopy

DOI 10.1055/a-2481-7048

ISSN 0013-726X

© 2024. European Society of Gastrointestinal Endoscopy.

All rights reserved.

This article is published by Thieme.

Georg Thieme Verlag KG, Oswald-Hesse-Straße 50, 70469 Stuttgart, Germany



Supplementary Material

Supplementary Material is available at

<https://doi.org/10.1055/a-2481-7048>

Corresponding author

Antonio Facciorusso, MD, PhD, Department of Experimental Medicine, Section of Gastroenterology, University of Salento, Piazza Filippo Muratore 1, 73100 Lecce, Italy
antonio.facciorusso@virgilio.it

MAIN RECOMMENDATIONS

1 ESGE recommends the combination of endoscopic ultrasound-guided tissue acquisition (EUS-TA) and endoscopic retrograde cholangiopancreatography (ERCP)-based tissue acquisition as the preferred diagnostic approach for tissue

acquisition in patients with jaundice and distal extrahepatic biliary stricture in the absence of a pancreatic mass.

2 ESGE suggests that brushing cytology should be completed along with fluoroscopy-guided biopsies, wherever technically feasible, in patients with perihilar biliary strictures.

3 ESGE suggests EUS-TA for perihilar strictures when ERCP-based modalities yield insufficient results, provided that curative resection is not feasible and/or when cross-

sectional imaging has shown accessible extraluminal disease.

4 ESGE suggests using standard ERCP diagnostic modalities at index ERCP. In the case of indeterminate biliary strictures, ESGE suggests cholangioscopy-guided biopsies, in addition to standard ERCP diagnostic modalities. Additional intraductal biliary imaging modalities can be selectively used, based on clinical context, local expertise, and resource availability.

ABBREVIATIONS

AE	adverse events
CA19–9	carbohydrate antigen 19–9
CBD	common bile duct
CCA	cholangiocarcinoma
CEA	carcinoembryonic antigen
CECT	contrast-enhanced computed tomography
CLE	confocal laser endomicroscopy
ERCP	endoscopic retrograde cholangiopancreatography
ERCP-TA	ERCP-based tissue acquisition
EUS	endoscopic ultrasound
EUS-TA	EUS-guided tissue acquisition
FNA	fine-needle aspiration
FNB	fine-needle biopsy
GRADE	Grading of Recommendations Assessment, Development and Evaluation
IDUS	intraductal ultrasound
IgG4	immunoglobulin G4 level
IgG4-SC	IgG4-related sclerosing cholangitis
PDAC	pancreatic ductal adenocarcinoma
PSC	primary sclerosing cholangitis
QALY	quality-adjusted life year
RCT	randomized controlled trial
SOC	single-operator cholangioscopy

SCOPE AND PURPOSE

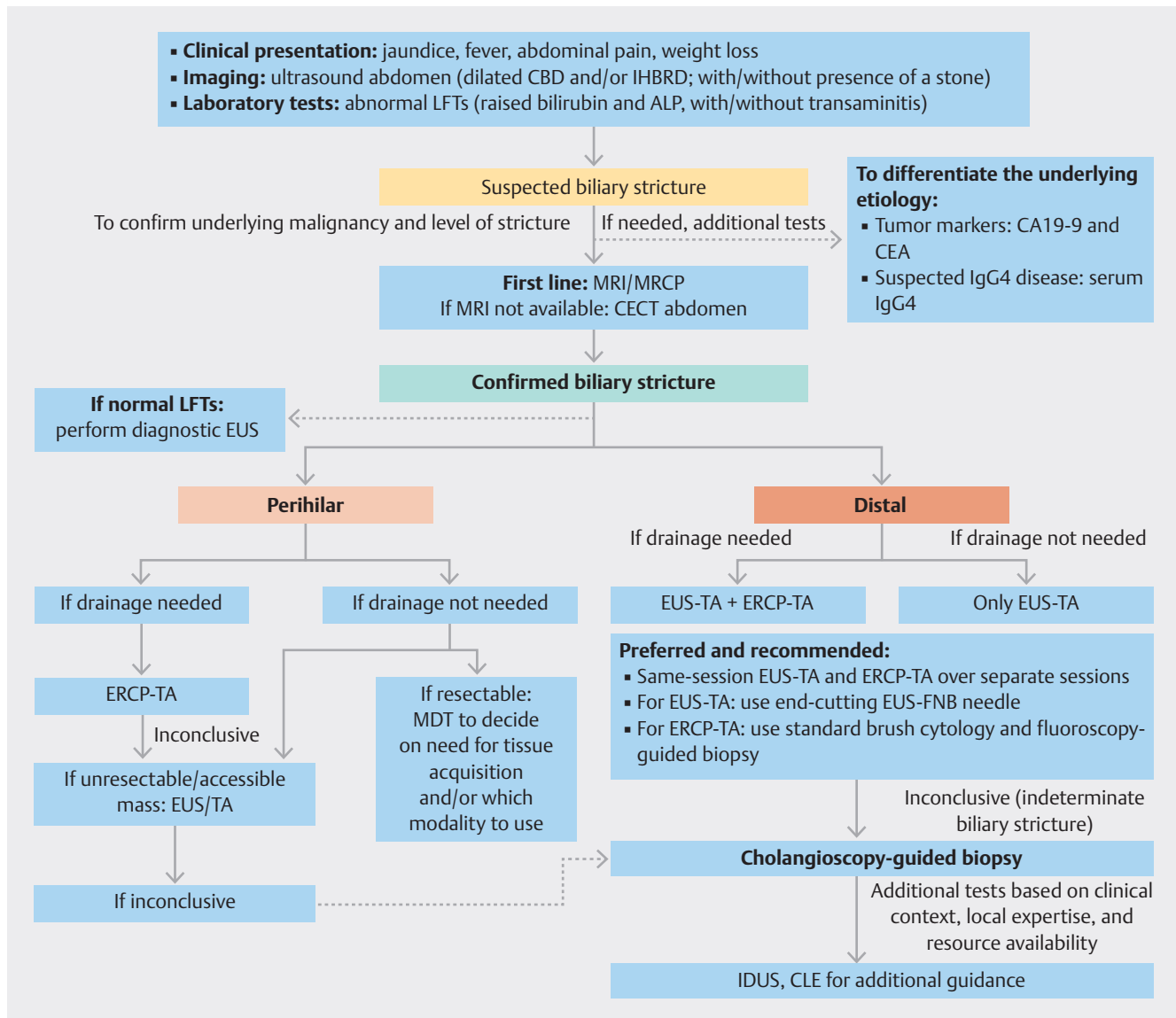
This Guideline is an official statement of the European Society of Gastrointestinal Endoscopy (ESGE). ESGE Guidelines represent a consensus of best practice based on the available evidence at the time of preparation. They are intended to be an educational tool to provide information that may support endoscopists in providing care to patients.

1 Introduction

A biliary stricture or bile duct stricture is defined as a narrowing or blockage of either the intrahepatic and/or extrahepatic biliary system, with concomitant upstream biliary duct dilatation, which impedes the antegrade flow of bile from the liver to the intestine. Symptomatic biliary strictures commonly present with jaundice (with/without cholangitis) and infrequently with liver abscess or secondary biliary cirrhosis. The most common benign etiology is iatrogenic injury, but it is determining the presence or absence of underlying malignancy that presents a diagnostic challenge for any clinician, as it has implications for oncologic and surgical decision-making.

The diagnostic armamentarium includes: laboratory tumor markers; cross-sectional imaging (computed tomography [CT], magnetic resonance imaging [MRI], and/or magnetic resonance cholangiopancreatography [MRCP]); endoscopic retrograde cholangiopancreatography (ERCP), which may include brushings, forceps biopsy, cholangioscopy-guided biopsy, and/or intraductal imaging; and endoscopic ultrasound (EUS), with/without fine-needle biopsy (FNB). The techniques for diagnosis and subsequent drainage (if needed) vary dependent on the anatomic location of the biliary stricture (intrahepatic, hilar, or extrahepatic) (► Fig. 1).

The European Society of Gastrointestinal Endoscopy (ESGE) commissioned this guideline in 2023 to deal specifically with the diagnostic approach to biliary strictures (not associated with an underlying pancreatic or abdominal mass). The goal of this guideline is to provide evidence-based recommendations (based on Grading of Recommendations Assessment, Development and Evaluation [GRADE] criteria), focusing on four separate sections: laboratory tests and cross-sectional imaging; extrahepatic biliary stricture; perihilar stricture; and cholangioscopy with intraductal imaging. The subject of endoscopic tissue sampling of pancreatic masses has already been discussed in a previous ESGE guideline [1], so has not been dealt with here.



► **Fig. 1** Proposed algorithm for the diagnosis of bile duct strictures.

ALP, alkaline phosphatase; CA19-9, carbohydrate antigen 19-9; CBD, common bile duct; CEA, carcinoembryonic antigen; CECT, contrast-enhanced computed tomography; CLE, confocal laser endomicroscopy; ERCP, endoscopic retrograde cholangiopancreatography; ERCP-TA, ERCP-based tissue acquisition; EUS, endoscopic ultrasound; EUS-FNB, EUS-guided fine-needle biopsy; EUS-TA, EUS-guided tissue acquisition; IDUS, intraductal ultrasound; IgG4, immunoglobulin G4 level; IHBRD, intrahepatic biliary radicle dilatation; LFTs, liver function tests; MDT, multidisciplinary team; MRCP, magnetic resonance cholangiopancreatography; MRI, magnetic resonance imaging.

2 Methods

The ESGE Guideline Committee Chair (K.T.) appointed a Leader (A.F.), who invited a list of authors (the panel) to participate in the project development, and four task forces were created to deal with the different aspects of the guideline. An online meeting was held on 22 June 2023, where task force members were allotted to different task forces and decisions were finalized on the subheadings for the Guideline and questions to be formed by each task force, as well as the deadline for the literature search and draft of the manuscript. All task force members were required to disclose potential financial and intellectual

conflicts of interest, which were addressed according to the ESGE policies.

The guideline was developed using the GRADE framework [2] (► **Table 1**). The relevant clinical questions were developed a priori and listed in the PICO format (**Table 1s**, see online-only Supplementary material).

Each task force performed a systematic literature search using PubMed/MEDLINE, Embase, Scopus, and the Cochrane library to identify publications from inception till December 2023 (restricted to papers published in the English language), focusing on meta-analyses and published prospective studies, particularly randomized controlled trials (RCTs), performed in humans (**Table 2s**). Retrospective analyses and pilot studies

► **Table 1** Interpretation of the certainty in evidence of effects and of strong and conditional recommendations using the Grading of Recommendations Assessment, Development and Evaluation (GRADE) framework.

Certainty	Description	
High	We are very confident that the true effect lies close to that of the estimate of the effect	
Moderate	We are moderately confident in the effect estimate. The true effect is likely to be close to the estimate of the effect, but there is a possibility that it is substantially different	
Low	Our confidence in the effect estimate is limited. The true effect may be substantially different from the estimate of the effect	
Very low	We have very little confidence in the effect estimate. The true effect is likely to be substantially different from the estimate of effect	
Implications	Strong recommendation	Conditional recommendation
For patients	Most individuals in this situation would want the recommended course of action and only a small proportion would not	Most individuals in this situation would want the suggested course of action, but many would not
For clinicians	Most individuals should receive the intervention. Formal decision aids are not likely to be needed to help individuals make decisions consistent with their values and preferences	Different choices will be appropriate for individual patients consistent with their values and preferences. Use shared decision-making. Decision aids may be useful in helping patients make decisions consistent with their individual risks, values, and preferences
For policymakers	The recommendation can be adapted as policy or performance measure in most situations	Policymaking will require substantial debate and involvement of various stakeholders. Performance measures should assess whether decision-making is appropriate

were also included if they addressed topics not covered in the prospective studies. For the purpose of the current guideline, only studies which pertained to “purely” bile duct strictures have been included when drafting the recommendations.

After further exploration of their content, all the relevant articles were included and summarized in the literature tables for the key topics.

Further details on the methodology of ESGE guideline development have been reported elsewhere [3]. In addition, various web meetings were held between the leader of the guideline (A.F.) and the task-force leaders to discuss and resolve issues, and to finalize the recommendations.

By September 2024, a draft of all of the recommendations in the Guideline was prepared by the listed authors. Following approval by the Leader (A.F.), the draft was reviewed by two members of the ESGE Governing Board and by external reviewers, and was then sent for further comments to the ESGE National Societies and individual members. After agreement on a final version, the manuscript was submitted to the journal *Endoscopy* for publication. All authors agreed on the final version of the manuscript.

This Guideline was issued in 2024 and will be considered for review if new and relevant evidence becomes available. Any updates to the Guideline in the interim period will be noted on the ESGE website: <https://www.esge.com/esge-guidelines.html>.

3 Results and recommendations

A summary of all recommendations is provided in ► **Table 2**.

The presence of a biliary stricture portends a medical challenge for any endoscopist, in terms of its anatomy and difficulty in making a diagnosis, and subsequently in deciding on its management [4]. Differentiating whether a biliary stricture is either

benign or malignant is of the foremost importance as it has implications in surgical and oncologic decision-making, hence the need to make a safe, accurate, and expedient diagnosis [5]. The gold standard has always been tissue diagnosis, wherein lies the role of endoscopy (ERCP or EUS) in providing cytologic or histologic specimens. Among the most common benign causes of biliary stricture is iatrogenic bile duct injury, whereas among malignant causes, pancreatic ductal adenocarcinoma (PDAC) and cholangiocarcinoma (CCA) are the commonest causes of distal and proximal stricture, respectively [6]. A list of the main etiologies of biliary stricture is shown in the list next page. Sometimes biliary strictures can present without an underlying mass, which occasionally makes them unidentifiable on cross-sectional imaging, as well as limiting the utility of tissue diagnosis in view of the desmoplastic nature of the tumors [7,8,9].

3.1 Laboratory tests and cross-sectional imaging

RECOMMENDATION 1

ESGE suggests against the use of tumor markers alone to discriminate between malignant and benign causes of a stricture in patients with suspected biliary stricture presenting with jaundice; ESGE suggests the use of laboratory tests in addition to other investigations (imaging and histopathology) in making a definite diagnosis. Conditional recommendation, very low quality of evidence.

Inexpensive and readily available serologic tests that can rapidly differentiate between benign and malignant causes of biliary stricture would allow prioritization of patients.

► **Table 2** ESGE recommendations on the diagnostic work-up of biliary strictures.

Recommendations	Strength of recommendation	Quality of evidence
1 ESGE suggests against the use of tumor markers alone to discriminate between malignant and benign causes of a stricture in patients with suspected biliary stricture presenting with jaundice; ESGE suggests the use of laboratory tests in addition to other investigations (imaging and histopathology) in making a definite diagnosis	Conditional	Very low
2 ESGE suggests the use of MRI/MRCP over CECT to discriminate between malignant and benign cause of obstruction and to detect the level of the stricture in patients with suspected biliary stricture presenting with jaundice and/or biochemical evidence of cholestasis	Conditional	Low
3 ESGE recommends the combination of EUS-TA and ERCP-TA as the preferred diagnostic approach for tissue acquisition in patients with jaundice and distal extrahepatic biliary stricture in the absence of a pancreatic mass	Strong	Moderate
4 ESGE suggests performing EUS and ERCP in the same session as this approach does not increase the risk of adverse events nor impair the effectiveness of the techniques	Conditional	Very Low
5 ESGE suggests performing EUS in patients with suspected biliary stricture and/or unexplained common bile duct dilatation even in the absence of abnormal laboratory tests	Conditional	Very Low
6 ESGE suggests that brushing cytology should be completed along with fluoroscopy-guided biopsies, wherever technically feasible, in patients with perihilar biliary strictures	Conditional	Low
7 ESGE suggests EUS-TA for perihilar strictures when ERCP-based modalities yield insufficient results, provided that curative resection is not feasible and/or when cross-sectional imaging has shown accessible extraluminal disease	Conditional	Low
8 ESGE suggests using standard ERCP diagnostic modalities at index ERCP. In the case of indeterminate biliary strictures, ESGE suggests taking cholangioscopy-guided biopsies, in addition to standard ERCP diagnostic modalities. Additional intraductal biliary imaging modalities can be selectively used, based on clinical context, local expertise, and resource availability	Conditional	Very Low

CECT, contrast-enhanced computed tomography; ERCP, endoscopic retrograde cholangiopancreatography; ERCP-TA, ERCP-based tissue acquisition; EUS, endoscopic ultrasound; EUS-TA, EUS-guided tissue acquisition; MRCP, magnetic resonance cholangiopancreatography; MRI, magnetic resonance imaging.

MAIN ETIOLOGIES OF BILIARY STRICTURES

Malignant

- Pancreatic cancer
- Cholangiocarcinoma
- Gallbladder cancer
- Hepatocellular carcinoma
- Ampullary cancer
- Lymphoma
- Rare neoplasia (cystadenocarcinoma, mixed hepatocellular-cholangiocellular cancer)
- Metastasis (colon cancer, breast cancer, renal cell cancer)

Fibroinflammatory

- Chronic pancreatitis
- Primary sclerosing cholangitis
- Autoimmune pancreatitis
- IgG4-mediated cholangitis
- Sarcoidosis
- Recurrent pyogenic cholangitis
- Extrinsic compression by pancreatic fluid collections

Iatrogenic

- Cholecystectomy
- Liver transplantation
- Local cancer treatment

Vascular

- Portal hypertensive biliopathy
- Ischemic biliary injury

Other

- AIDS cholangiopathy
- Mirizzi syndrome

AIDS, acquired immunodeficiency syndrome; IgG4, immunoglobulin G4.

The two most commonly studied tumor markers related to the pancreaticobiliary system are the carbohydrate antigen 19–9 (CA19–9) and carcinoembryonic antigen (CEA). Both are glycoprotein tumor markers with the immune-determinant epitope on the carbohydrate and protein moiety of the molecule, respectively [10, 11].

3.1.1 Benefits

The usefulness of these tumor markers has been shown in multiple studies, regarding their role in staging, evaluation of resectability status, and assessment of prognosis and of recurrence on follow-up [12, 13, 14, 15, 16].

The panel conducted a comprehensive meta-analysis to determine the accuracy of CA19–9 and CEA levels in differentiating benign versus malignant etiologies. After a comprehensive literature search, 11 studies for CA19–9 [17, 18, 19, 20, 21, 22, 23, 24, 25, 26, 27] and four studies for CEA levels [26, 28, 29, 30] were selected for analysis (inclusion criteria: CA19–9 >37 U/mL and CEA >2.5–5 ng/mL, with studies reporting the accuracy of malignant vs. benign cases) (**Table 3s**). The pooled accuracy of CA19–9 levels for discrimination between benign and malignant causes of biliary stricture was 81% (95%CI 76%–87%; $I^2 = 84.7\%$) (**Fig. 1s, part a**), whereas the pooled accuracy of CEA levels was 70% (95%CI 62%–78%; $I^2 = 63.7\%$) (**Fig. 1s, part b**). For malignant cases, the sensitivity of CA19–9 levels was 68%–85%, with a specificity of 64%–87%. Similarly, for CEA levels, the sensitivity and specificity were 25%–82% and 83%–92%, respectively.

Morris-Stiff et al. have also reported that the combination of tumor markers (CA19–9) with cross-sectional imaging increases the sensitivity and specificity from 85% to 97% and 70% to 89%, respectively [21]. Similarly, the decline in CA19–9 post-biliary drainage is slower, and the average reduction is smaller in malignant cases (50%) compared with benign cases (100%) [17]. All these factors highlight that the role of tumor markers (especially CA19–9 and CEA) is complementary to other investigations, like cross-sectional imaging and tissue diagnosis, for determining the underlying etiology of biliary strictures.

Additionally, when IgG4-related sclerosing cholangitis (IgG4-SC) is clinically suspected, especially in a setting of distal common bile duct (CBD) stricture and autoimmune pancreatitis, serologic testing in the form of serum IgG4 levels is usually the first-line investigation, having been reported to be elevated in 90% of IgG4-SC cases [31, 32].

3.1.2 Harms

Numerous studies have reported elevated CA19–9 levels (>37 U/mL) in various pancreaticobiliary cancers (especially PDAC, CCA, and gallbladder cancer). CA19–9 proved a more useful marker in the absence of cholestasis or cholangitis (sensitivity 78% vs. 74%; specificity 83% vs. 42%) [33]. Increasing the cutoff value decreases the sensitivity and precludes its clinical utility. CA19–9 has also been shown to be elevated in a number of benign conditions, such as liver diseases (primary sclerosing cholangitis [PSC] and cirrhosis, among others), obstructive jaundice, pancreatitis, and even in renal, respiratory, and rheumatologic cases [34]. Moreover, CA19–9 antigen is an oligosac-

charide corresponding to sialylated Lewis blood group Le^a , whose concentration in serum may be influenced by the patient's secretor status and Lewis genotype [35] (7% of the world's population are nonsecretors). As a result, such false-positive cases are to be interpreted with caution.

As evident in the meta-analysis above, both tumor markers have low pooled accuracy in identifying malignancy as a cause of biliary obstruction. Moreover, high false-positive rates of CA19–9 and CEA have been reported (15% and 18%, respectively) [19]. Higher cutoff values for CA19–9 were suggested in a few studies (e.g. 90 U/mL and 70.5 U/mL), which further decreased the sensitivity [17, 21].

Although the serum IgG4 level is a piece of the diagnostic evidence when IgG4-SC is suspected, its specificity is suboptimal to be used in isolation, without other criteria. Kamisawa et al. reported using a cutoff of >135 mg/dL along with both imaging and histopathologic evidence to formulate a definitive diagnosis [36]. Its sensitivity and specificity are 64%–90% and 87%–93%, respectively [31, 36, 37].

Elevated levels of serum IgG4 have also been reported in patients with CCA (8%–14% of patients), PSC (9%–22%), and pancreatic cancer (6%) [31, 37, 38, 39]. Therefore, owing to the low discrimination value of serum IgG4 levels when used alone and frequent false positives in various diseases, especially PSC and CCA (which may mimic IgG4-SC), IgG4 levels should not be used alone for the diagnosis of IgG4-SC, but only in combination with imaging and histopathology.

In conclusion, laboratory tests and serum tumor markers alone have an unacceptably low accuracy in differentiating between benign and malignant biliary obstruction, especially in the presence of jaundice or cholangitis.

3.1.3 Cost-effectiveness profile

Although measurement of tumor markers is relatively inexpensive, the costs associated with searching for malignancy on the basis of an isolated finding of an elevated tumor marker can amount to thousands of dollars, for example US\$34685 for ERCP and \$37458 for EUS according to a recent cost-effectiveness analysis [40]. Therefore, although specific cost-effectiveness analyses on the use of tumor markers in biliary strictures are lacking, the unacceptably low accuracy of tumor markers alone in detecting neoplasia would determine an increase in the costs of missed diagnoses and an overuse of cross-sectional imaging and endoscopy in false-positive cases.

3.1.4 Environmental impact

Laboratory buildings, processes, and equipment, including single-use plastics, automation, and technologies using vast amounts of energy and water, along with transportation and storage of samples, all add to the environmental burden. Among the suggestions to reduce the carbon footprint in this setting are recycling bins in all laboratory and nonlaboratory areas, reviewing freezer contents regularly and discarding items not needed, performing audits to reduce printing, storing work logs digitally to reduce printing, nonlaboratory staff working from home on a rota basis, using timers or labelling to switch off nonessential equipment when not in use, and using

electronic signatures. Furthermore, reducing sample transport and finding more efficient means of transport represent another challenge to improve this aspect [41].

3.1.5 Certainty of the evidence assessment

The risk of bias assessment for each study can be found in **Table 4s**. Overall, all the included studies were considered to be of good quality. The certainty of evidence in this PICO question was downgraded owing to the fact that there were only non-comparative observational studies included (**Table 5s**). For the main outcome of diagnostic accuracy, further downgrading was applied owing to inconsistency (high heterogeneity), which downgraded the quality of evidence to very low.

RECOMMENDATION2

ESGE suggests the use of MRI/MRCP over contrast-enhanced computed tomography (CECT) to discriminate between malignant and benign causes of obstruction and to detect the level of the stricture in patients with suspected biliary stricture presenting with jaundice and/or biochemical evidence of cholestasis.

Conditional recommendation, low quality of evidence.

The expanding spectrum of therapeutic interventions for the management of biliary stricture mandates that a precise assessment be made beforehand regarding the etiology, location, level, and extent of the disease. This diagnostic algorithm usually follows a two-pronged approach: initial clinical and laboratory examination, followed by cross-sectional imaging. Any imaging procedure that is undertaken should answer two important questions: etiology (benign vs. malignant) and the level of the stricture. The role of imaging in the evaluation of any case of biliary stricture entails confirming the diagnosis (benign vs. malignant), locating the level of stricture (distal, mid, or hilar), staging the disease, assessing the resectability status, and giving preoperative information to the surgeon by providing a proper roadmap and the relevant anatomic and vascular anatomy.

Transabdominal ultrasound has low accuracy in determining the etiology and extent of the disease, with a sensitivity and specificity for biliary obstruction of 31%–100% and 71%–97%, respectively [42,43,44]. In contrast, ERCP (the gold standard) remains the cornerstone in the management of biliary strictures, offering simultaneous tissue diagnosis, but is burdened with complications (4%–10%), such as post-ERCP pancreatitis, bleeding, infection, and perforation, meaning its role for diagnostic purposes has become outdated [42,43,45].

3.1.6 Benefits

MRCP is noninvasive, and does not require contrast injection and ionizing radiation exposure, with minimal risk of post-procedure complications. It provides a panoramic view of the biliary tree (multiplanar capability), both above and below the stricture, which enables diagnosis of the site, nature, and

dimensions of the obstruction, providing a complete overview of the biliary tree to the endoscopist/surgeon. When combined with MRI, it allows indirect visualization of drainage catheters and preoperative evaluation of the extent of disease (staging), which is especially useful in those with altered anatomy. Meanwhile, a contrast-enhanced computed tomography (CECT) scan is quick, with few motion artifacts, and with good patient compliance; however, it involves exposure to radiation and intravenous contrast agents. All these factors give MRI/MRCP a “theoretical edge” over CECT scanning for the evaluation of any cases of biliary stricture [6,46].

For the evaluation of obstructive jaundice, the published literature reports a sensitivity, specificity, and accuracy of MRCP of 81%–100%, 84%–100%, and 90%–96%, respectively [47]. Likewise, a CECT abdomen is highly sensitive (74%–96%) and specific (90%–94%) for the detection of biliary obstruction [42,43,44]. Both modalities can also detect vascular encasement and metastatic disease.

The panel conducted a comprehensive meta-analysis to assess the pooled accuracy of CECT versus MRI/MRCP in determining the level of biliary stricture and malignancy as the etiology. Only head-to-head comparative studies were taken into consideration. For determination of the level of stricture, six studies were analyzed [48,49,50,51,52,53] (**Table 6s**), wherein the pooled accuracy of MRI/MRCP was superior to that of CECT (odds ratio [OR] 3.3, 95%CI 1.2–9.1; $I^2=0\%$) (**Fig. 2s, part a**).

Similarly, 10 studies [47,49,50,51,53,54,55,56,57,58] were analyzed for the pooled accuracy of diagnosing malignant biliary strictures (**Table 7s**), wherein MRI/MRCP again proved superior to CECT (96% vs. 89%; OR 2.1, 95%CI 1.2–3.6; $I^2=12\%$) (**Fig. 2s, part b**). Furthermore, MRI/MRCP has also been shown to avoid the need for unnecessary ERCP in approximately one-third of cases [59], is valuable in the setting of failed ERCP, and offers incremental benefit over ultrasound in pregnant patients with suspected biliary obstruction. MRI/MRCP is also useful in planning for therapeutic ERCP in difficult situations, such as complex hilar strictures, or where additional pancreatic therapy is being contemplated [60,61].

In conclusion, based on the evidence above, ESGE suggests that, in a suspected case of biliary stricture with/without jaundice, MRI/MRCP should be preferred over CECT for the evaluation of both the level and the underlying pathology of the biliary stricture.

3.1.7 Harms

Even though MRCP is superior to CECT in evaluating the cause and level of a biliary stricture, both have their own sets of limitations. Both are operator-dependent modalities, and their diagnostic accuracy varies with the available expertise [62].

Contraindications for the use of MRI/MRCP include the presence of underlying pacemakers, cerebral aneurysm clips (although MRI-compatible devices are now available), and claustrophobia. Furthermore, technical considerations, such as breath-holding, lack of therapeutic ability, and motion artifacts, limit its usefulness in certain situations. The latter leads to poor sensitivity of MRCP for the detection of small stones

(<3–5 mm; 64%), as reported by Guibaud et al. [63]. Motion artifacts are prevalent in the distal portion of the CBD, where small stones usually migrate, thereby decreasing resolution, which has been shown to translate into lower performance for MRCP when evaluating distal over proximal strictures [64]. By extrapolation of these findings, ampullary pathologies may be erroneously diagnosed because of poor performance of MRCP at/near the duodenal wall. A meta-analysis of 67 studies by Romagnuolo et al. reported that a negative MRCP did not exclude a diagnosis, if the pretest suspicion of malignancy was high, with suspicion only reduced by 10% by a normal MRCP [65].

Similarly, in patients with known hypersensitivity or allergy to contrast agents, or chronic kidney disease, CECT scanning is seldom used. The use of contrast agents is a major limitation to the use of CECT, as CECT formulates a diagnosis of luminal or extraluminal pathology based on enhancement patterns and attenuation value in the portal venous phase. In addition, radiation exposure is another factor that gives MRI/MRCP an edge over CECT for the evaluation of biliary diseases. The increasing use of CECT has heightened concerns about relatively large cumulative exposure to radiation owing to repeated examinations. The average typical effective doses for a basic CT of the abdomen and the chest are 8 mSv and 7 mSv, respectively [66], although the cancer risk is negligible when examined from a population level. Extrapolation of data from lung cancer screening clearly shows that the benefits of using CECT scanning at present outweigh the risks associated with cumulative exposure to radiation [67], provided it is not used for asymptomatic cases.

3.1.8 Cost-effectiveness profile

Performing MRI/MRCP prior to ERCP in planning for a subsequent therapeutic strategy has been shown to be a more cost-effective approach for biliary diseases. Howard et al. reported, in a probabilistic sensitivity analysis, that with a low–moderate probability of bile duct stones in a post-cholecystectomy situation, there was a 59% likelihood of MRCP being a cost-saving procedure, with an 83% chance that MRCP had a cost-effectiveness ratio more favorable than \$50 000 per quality-adjusted life year (QALY) gained [68]. Similar findings were echoed by Vergel et al., wherein MRCP was both cost-effective and showed improved quality of life outcomes, compared with diagnostic ERCP [69].

3.1.9 Environmental impact

A recent systematic review highlighted that the energy consumption of diagnostic radiology devices, such as MRI and CECT scanners, constitutes a significant portion of the overall energy usage in a radiology department [70]. Interestingly, this systematic review reported that a considerable percentage (40%–91%) of the energy consumption of these devices was defined as nonproductive, emphasizing the need to optimize device usage and reduce idle times [70]. Other sustainability actions were shown to be implementing informatic tools for workflow and optimizing operating modes, with estimated annual savings ranging from 14 180 to 171 000 kWh [70]. For MRI, the carbon footprint associated with the entire individual ser-

vice has been measured up to a maximum of 22.4 kg CO₂-equivalents, as Scope 2 and Scope 3 emissions. This value includes both in-hospital process energy (29 kWh per patient) and out-of-hospital energy (about 75 kWh per patient), which is required not only for electricity generation during its medical use but also for the manufacturing of the MRI scanner itself and the disposable and reusable products used during diagnostic activities [71]. Only approximately 28% of the total MRI life-cycle energy is used for image acquisition, suggesting potential improvements to reduce the environmental impact [71].

3.1.10 Certainty of the evidence

The risk of bias assessment for each study can be found in **Table 8s**. Overall, the included studies were considered to be of good quality. The certainty of evidence for all clinical outcomes in this PICO question was downgraded because the evidence was based only on nonrandomized observational studies in the absence of RCTs (**Table 5s**). Therefore, for both the outcomes of diagnostic accuracy for the detection of the obstruction level and of determining the malignant etiology of the stricture, the quality of evidence was rated as low and a conditional recommendation was proposed.

3.2 Distal biliary strictures

RECOMMENDATION 3

ESGE recommends the combination of EUS-guided tissue acquisition and ERCP-based sampling as the preferred diagnostic approach for tissue acquisition in patients with jaundice and distal extrahepatic biliary stricture in the absence of a pancreatic mass.

Strong recommendation, moderate quality evidence.

Tissue sampling to establish the nature of the stenotic lesion is a key step in the diagnostic work-up of biliary strictures. Although these strictures can be due to both extrinsic compression and intrinsic pathologies, the current guideline will be limited to bile duct lesions only.

It is already known that a significant proportion (70%–80%) of biliary strictures are malignant, with the risk of malignancy being higher in patients with a definitive mass on cross-sectional imaging than in those with no clear mass lesion [72]. Early diagnosis is therefore important in directing patients to the proper therapeutic strategy. While transpapillary brush cytology or forceps biopsy after sphincterotomy during ERCP (ERCP-TA) have been the standard sampling modality, EUS-guided tissue acquisition (EUS-TA) has become a useful addition to the diagnostic armamentarium over time. The pooled sensitivities of brush cytology and intraductal biopsies were found to be 45% and 48%, respectively, while the combination of the two only modestly increased the sensitivity to 59% [73]. In contrast, EUS-TA has been reported to have a pooled diagnostic sensitivity of 83% for distal biliary strictures [74]. The appropriate choice of modality will depend not only on the availability of suitable expertise, but also on the location of the lesion and

the presence of jaundice. Indeed, EUS-TA has shown better sensitivity for distal lesions compared with proximal lesions [74]. Moreover, in the absence of jaundice, ERCP-TA should be avoided.

3.2.1 Benefits

The task force performed a meta-analysis of eight studies [75, 76, 77, 78, 79, 80, 81, 82] directly comparing EUS-TA with ERCP-TA for cases requiring additional biliary drainage for jaundice and the characteristics of these studies are outlined in **Table 9s**. EUS-TA performed significantly better than ERCP+brushing (ERCP+brushing vs. EUS-TA: OR 0.31, 95%CI 0.12–0.77; $I^2=75\%$) and with a nonsignificant trend even against ERCP-biopsies (ERCP-TA vs. EUS-TA: OR 0.66, 95%CI 0.38–1.16; $I^2=0\%$) (**Fig. 3s**).

EUS-TA is superior owing to the fact that EUS can enable optimal visualization of the distal bile duct mass or thickening thereby appropriately targeting the lesion. In fact, bile duct masses as small as 5mm or a wall thickness of >3mm have been shown to be best suited for EUS-TA [75, 83]. Moreover, a meta-analysis (10 studies, 1162 patients) has shown that there is a 14% incremental benefit of EUS for achieving the diagnosis after nondiagnostic brush cytology [84]. EUS can aid in tumor staging and access to regional or distant lymph nodes or distant metastases.

The panel analyzed the diagnostic potential of combining the two endoscopic procedures (EUS-TA and ERCP-TA) for biliary stricture, based on three studies [75, 76, 77]. The diagnostic accuracy for the combined approach was 93%–98% compared with 76%–94% and 55%–81% for EUS-TA only and ERCP-TA only, respectively. The combined approach was significantly superior (**Fig. 4s**): EUS-TA+ERCP vs. ERCP-TA alone, OR 6.2, 95%CI 2.7–13.9; $I^2=33\%$; EUS-TA+ERCP vs. EUS-TA alone, OR 2.6, 95%CI 1.4–5.1; $I^2=0\%$).

This strategy of combining EUS and ERCP is likely to help in reducing the grey zone of nondiagnostic or indeterminate biliary strictures, when the diagnostic procedures have to be further optimized; however, a negative report for either EUS-TA or ERCP-TA cannot exclude malignancy as both have low post-test probabilities [84].

3.2.2 Harms

While there are no data directly comparing ERCP-TA with EUS-TA for patients without jaundice, meaning they do not require biliary drainage, we could suggest the use of only EUS-TA over ERCP-TA, given the better performance of EUS-TA and the adverse events (AEs) associated with ERCP, which include post-ERCP pancreatitis, cholangitis, duodenal perforation, and bleeding. Although targeting a thickened stenotic area or mass at the lower end of the bile duct is technically easier, a theoretical risk of penetrating a nondrained biliary system leading to bile leak or intracholedochal bleeding should be considered. Nevertheless, the pooled rate of AEs for EUS-TA for biliary strictures is 1%, with the majority of AEs being mild and self-limiting [74].

Despite the available data, there are certain caveats to its interpretation with respect to current practice. While most of

the EUS-TAs reported in the above-mentioned studies consisted of EUS-guided fine-needle aspirations (EUS-FNAs), it is EUS-FNB needles that are now commonly used worldwide. With the advent of the newer generation of end-cutting biopsy needles, FNB has been found to be superior to FNA [85] in terms of tissue yield. Therefore, with EUS-FNB, the yield of EUS-TA for distal biliary strictures is expected to improve further, although we still need more data. Similarly, needle size and ancillary suction techniques are other areas of contention [86] that might need answers in order to optimize EUS-TA in distal biliary strictures.

3.2.3 Cost-effectiveness profile

The cost-efficacy of combining EUS-TA and ERCP-TA has not been investigated.

3.2.4 Environmental impact

Gastrointestinal endoscopy is an intensive procedure with significant contributions to greenhouse gas emissions [87]. Until studies addressing the ecologic impact of endoscopy in diagnosing distal biliary strictures become available, adherence to guidelines is paramount to assure the lowest possible environmental impact while maintaining a good quality of the medical act [88]. In this regard, audit of the procedural diagnostic yield and maintenance of a good standard of quality in endoscopy also avoids unnecessarily repeating endoscopic procedures and reduces their environmental impact.

3.2.5 Certainty of the evidence

The risk of bias assessment for each study included in the meta-analysis can be found in **Table 10s**. Although based only on retrospective studies, the high quality of the studies, lack of imprecision/indirectness/inconsistency, and, above all, the high magnitude of the effect (OR of the combined diagnostic approach >5 vs. ERCP alone and >2 vs. EUS alone) led to uprating of the level of evidence and the strength of recommendation, as per GRADE policy (**Table 5s**).

RECOMMENDATION 4

ESGE suggests performing EUS and ERCP in the same session as this approach does not increase the risk of adverse events nor impair the effectiveness of the techniques. Conditional recommendation, very low quality of evidence.

Patients with jaundice due to extrahepatic biliary strictures may require both tissue sampling and biliary drainage. There are no dedicated studies comparing the outcomes of the strategy of performing EUS-TA and ERCP separately or in the same session for isolated biliary strictures; however, evidence may be extrapolated from six studies (five retrospective and one RCT) that cover a wide range of benign and malignant pathology, with the majority of lesions being pancreatic masses [89, 90, 91, 92, 93, 94].

3.2.6 Benefits

Table 11s reports the baseline characteristics of these six studies [89,90,91,92,93,94]. On analysis, same-session EUS and ERCP had similar cannulation rates (OR 1.0, 95%CI 0.3–2.9; $I^2=11\%$) compared with separate session procedures (**Fig. 5s, part a**). Performing both procedures in the same session has the benefit of improved tissue diagnosis from the combined approach, as mentioned previously.

In the only prospective RCT, 180 patients with suspected distal obstructive jaundice were randomized into three groups: single-session EUS and ERCP, EUS and ERCP in different sessions, and ERCP-only groups [91]. Performing the two procedures in the same session required similar procedure times when compared with separate sessions, while anesthetic and endoscopic complications were similar among all three groups [91]. Aslanian et al. have pointed out that the same-session approach had lower anesthesia requirements [89]. These data tend to favor the combined EUS and ERCP approach, preferably in the same session whenever possible, for reasons of procedural optimization and better patient comfort.

Moreover, where EUS was performed first, it was possible to avoid ERCP in four cases in the study by Chu et al. [91]. Therefore, the EUS findings can be regarded more as a roadmap to better understand the anatomy of the obstructed biliary system and guide the therapeutic endoscopic procedures. Finally, a more expedited patient evaluation, the avoidance of repeated sedation [89], a shorter time to chemotherapy [93], shorter hospitalization, and lower costs [95] are potential benefits of the combined procedures.

3.2.7 Harms

On analysis, same-session EUS and ERCP did not produce an increase in AEs (OR 1.2; 95%CI 0.7–2.0; $I^2=20\%$) compared with separate sessions (**Fig. 5s, part b**).

Our analysis did not find differences in the overall AE rate between single and separate sessions for EUS-TA and ERCP; however, the included studies mainly referred to pancreatic masses. For biliary lesions, the risk of AEs may be higher. First, the main pancreatic duct is rarely stenotic in pure biliary lesions, increasing the risk of post-procedural pancreatitis. Second, the smaller size of biliary lesions compared with pancreatic masses and the transbulbar approach that is often used during biliary tumor biopsies make puncture of the lesion more challenging. These harms seem however to be related to the type of lesion and may be independent of the sequence/combination of the two procedures.

Performing EUS-TA and ERCP during the same session may require a longer duration of sedation for the session, potentially resulting in greater use of general anesthesia [89,93]; however, amounts of anesthetic drugs used in the combined procedure seem to be lower than in separate sessions [89,94] and anesthesia-related AEs do not differ between the two strategies [93,94]. Vila et al. reported three desaturations (one requiring orotracheal intubation and one evolving into aspiration pneumonia) in the same-session EUS and ERCP group, and one desaturation in the separate sessions group, with no significant differences found [94].

3.2.8 Cost-effectiveness profile

One retrospective single-center study addressed the cost of combined EUS and ERCP considering the costs of endoscopic instruments, single-use endoscopic devices, anesthetic drugs, procedure duration, and hospitalization days [95]. The authors compared the estimated costs of the single-session strategy with the expected costs of separate sessions, calculating a cost-saving of €510 per patient in the subgroup of patients who underwent single-session EUS-FNA and ERCP for malignant lesions, mainly owing to reduced hospitalization time, procedure duration, and professional fees.

3.2.9 Environmental impact

The coupling of the two procedures in the same session theoretically brings the advantage of lower energy requirements for sedation, postprocedural monitoring, and hospitalization, therefore theoretically this recommendation should decrease the environmental footprint of the endoscopic endeavor in diagnosing distal biliary strictures. However, further studies are necessary to specifically address this issue.

3.2.10 Certainty of the evidence

The risk of bias assessment for each study can be found in **Table 12s**. The certainty of evidence for all clinical outcomes in this PICO question was downgraded owing to the fact that it was mainly noncomparative observational studies that were included (**Table 5s**). For the two outcomes of cannulation rate and AE rate, further downgrading was applied because of imprecision (wide CIs crossing 1), which downgraded the quality of evidence to very low.

RECOMMENDATION 5

ESGE suggests performing EUS in patients with suspected biliary stricture and/or unexplained common bile duct dilatation even in the absence of abnormal laboratory tests. Conditional recommendation, very low quality of evidence.

With the widespread use of high resolution cross-sectional imaging (CECT, MRI, and MRCP), the incidental finding of CBD dilatation without symptoms and with normal liver function tests is being increasingly discovered. A dilated CBD is defined as having a diameter of ≥ 7 mm and is commonly encountered in older people, and those with previous cholecystectomy or chronic narcotic use [96,97,98]. In the absence of any identifiable etiology on imaging, in clinical practice, these patients are usually referred for EUS examination; however, there is scarce literature on the yield of EUS in this setting. Moreover, a further challenging scenario could be the assessment of the ampulla, where flat lesions can be missed during cross-sectional imaging and EUS evaluation. Although evidence in the literature is lacking, the use of side-viewing endoscopes/duodenoscopes for ampullary assessment in patients with distal biliary stricture without a detectable mass could be a useful addition to the diagnostic algorithm in this specific setting.

3.2.11 Benefits

The task force performed a meta-analysis, finding seven retrospective studies and one previous meta-analysis focusing on the diagnostic value of EUS for this indication (**Table 13s**) [99, 100, 101, 102, 103, 104, 105, 106].

The rate of abnormal findings in these studies was 6% to 35%, with the etiologies being mostly benign (CBD stones in a large majority) and very rarely malignant (0%–5% for ampullary and pancreatic tumors). Oppong et al. demonstrated that previous cholecystectomy is significantly associated with negative EUS findings in the group of patients with isolated CBD dilatation ($P=0.005$) [106]. In the study of Kaspy et al., univariate, bivariate, and multivariate logistic regression analyses demonstrated significant negative associations between an EUS finding of CBD stones or sludge with history of cholecystectomy (OR 0.23; $P=0.03$) and age <65 years (OR 0.05; $P=0.03$), with mean age tending to be higher in patients with CBD stones or sludge (78 vs. 66 years; $P=0.07$) [103]. In contrast, they found no association between symptoms (biliary-type abdominal pain) and EUS diagnosis of CBD stone or sludge.

The yield of EUS examination in this setting was evaluated in a systematic review and meta-analysis by Chhoda et al. that included eight full manuscript studies and three conference abstracts [99]. Among 224 asymptomatic patients with CBD dilatation, the cumulative yield of EUS for any pathology was 11% (95%CI 4%–22%) [99]. The EUS yield for benign etiologies was 9% (95%CI 1%–22%), including choledocholithiasis (3%, 95%CI 0%–11%), whereas for malignant pathology it was 5% (95%CI 0%–3%) [99].

The meta-analysis of the available data showed a rate of abnormal findings of 15% (95%CI 9%–21%), whereas the rate of malignancy was <0.1% (95%CI 0%–0.1%) (**Fig. 6s**).

Despite their limitations (retrospective single-center design, limited sample size, and heterogeneity of the outcome measures), all these studies showed a low, but not insignificant, rate of benign abnormal conditions (most commonly CBD stones) during endosonographic exploration of asymptomatic biliary dilatation, demonstrating the potential benefit of performing EUS in patients with suspected biliary stricture even in the absence of abnormal laboratory tests. Based on the evidence above, the panel suggests the use of EUS in this setting, even though neoplastic conditions are extremely rare.

3.2.12 Harms

No AEs were reported in patients undergoing EUS exploration for suspected biliary structures with normal laboratory tests. Diagnostic EUS is considered a low risk procedure, with rare complications such as bacteremia, bleeding, duodenal perforation, and sedation-related complications, comparable with that of diagnostic upper gastrointestinal endoscopy [107] and must be factored against the diagnostic yield of EUS, after shared decision-making with the patient.

3.2.13 Cost-effectiveness profile

Despite its resource use, EUS seems cost-effective for this indication by avoiding additional imaging examinations when no pathologic finding is detected.

3.2.14 Environmental impact

In a context where the rate of malignancy is <0.1% (as presented above), justification for a resource-intensive endoscopic procedure that is a generator of greenhouse gasses and waste is easily debatable. Because appropriateness criteria are not perfect, they should always be combined with clinical judgment, with case-by-case analysis and decision-making warranted in this context [88].

3.2.15 Certainty of the evidence

The risk of bias assessment for each study can be found in **Table 14s**. The certainty of evidence for all clinical outcomes in this PICO question was downgraded owing to the fact that there were only noncomparative observational studies included (**Table 5s**). For the two outcomes of pooled malignancy rate and rate of abnormal findings, further downgrading was applied because of inconsistency (high heterogeneity), so downgrading the quality of evidence to very low.

3.3 Perihilar biliary strictures

RECOMMENDATION 6

ESGE suggests that brushing cytology should be completed along with fluoroscopy-guided biopsies, wherever technically feasible, in patients with perihilar biliary strictures.

Conditional recommendation, low quality of evidence.

A recent meta-analysis of 21 observational studies [108] concluded that fluoroscopy-guided biopsies plus brush cytology during ERCP for the evaluation of biliary strictures could lead to a 20% increased diagnostic yield (95%CI 9%–31%) for malignancy versus brush cytology alone. Moreover, the combination of fluoroscopy-guided biopsies and brush cytology was associated with the highest sensitivity (66%, 95%CI 63%–69%) compared with brush cytology alone (40%, 95%CI 37%–43%) and fluoroscopy-guided biopsies alone (52%, 95%CI 49%–56%). Of interest, this analysis included both proximal and distal strictures with no difference found between them in terms of outcome on subgroup analysis. It should be acknowledged that intraductal fluoroscopy-guided biopsies are more demanding and technically challenging, asking for advanced expertise. In addition, one should keep in mind that intraductal biopsies carry a risk of complications such as bleeding, duodenal or bile duct perforation, and pancreatitis, and so, whenever possible, previous multidisciplinary team discussion is recommended in order to decide on the optimal approach.

3.3.1 Benefits

The panel did not identify any RCTs evaluating cytology brushing versus fluoroscopy-guided biopsies, or their combination for proximal biliary strictures. Two cohort studies [109, 110] comparing the efficacy of brushing, fluoroscopy-guided biopsies, and their combination for proximal biliary strictures were retrieved (**Table 15s**). In the first study, 58 patients with hilar

CCA were included and the sensitivities of brushing cytology, fluoroscopy-guided biopsies, and their combination were 41%, 53%, and 60%, respectively [109]. In the second study, 43 patients with proximal biliary strictures were enrolled and underwent both cytology brushing and fluoroscopy-guided biopsies using a particular double-balloon enteroscopy forceps that was advanced to the point of interest through a plastic pusher after removal of the guidewire [110]. The sensitivity of brushing cytology was 49%, but was 69% for fluoroscopy-guided biopsies, and increased to 80% when both methods were combined.

The meta-analysis of these two studies showed an incremental diagnostic yield of 25% (95%CI 11%–38%; $P<0.001$; $I^2=0\%$) (**Fig. 7s, part a**) and a significantly increased sensitivity (OR 2.7, 95%CI 1.5–4.9; $P<0.001$; $I^2=0\%$) (**Fig. 7s, part b**) for diagnosing malignancy when adding fluoroscopy-guided biopsies to brushings in perihilar biliary strictures.

Transpapillary biopsies can be performed with standard biopsy forceps. Nevertheless, studies evaluating slim forceps with a design that allows the angle of the forceps to be modified have shown good results [111,112] that appear to be even better than those obtained with conventional biopsy forceps [113].

Some reports have shown an increase in diagnostic yield with an increasing number of biopsies: in a retrospective study, after three or more biopsies, a sensitivity of 100% was found [114] and, in a prospective study of 31 patients, the reported sensitivity was 55% after three biopsies, and 59% after four or more biopsies [115]. However, in the most recent meta-analysis available, when comparing the 13 studies that reported the number of biopsies taken in each study, there was no difference in sensitivity between studies that performed fewer than four biopsies and studies that performed four or more biopsies (69% vs. 70%) [116]. Therefore, three to four biopsies may be an adequate number.

Several technical variants have been described to facilitate the ascent of the biopsy forceps through the bile duct with good results. Although the evidence comes from small series, given the difficulty of access and lower diagnostic yield in biliary strictures with more proximal locations, it may be useful to use guidance systems to reach such strictures [117,118,119,120].

Studies of dilation of the stenosis prior to biopsy are scarce and, although it appears to increase diagnostic yield without increasing complications, there are insufficient data to recommend its routine use [121,122].

The evaluation of different brushes over several studies has not shown a significant increase in diagnostic performance that would justify the use of any biliary brushes other than the conventional ones [123,124,125].

Recent data from a multicenter RCT with more than 400 included patients showed that the sensitivity of cytology increased with the number of the brush passes [126]. In this study, the sensitivities were 38%, 47%, and 57% when 10, 20, and 30 brush passes were performed, respectively. These results encourage increasing the number of brush passes beyond 10, as this measure would barely increase procedural

time and AEs, and would improve the diagnostic performance of the technique.

3.3.2 Harms

The previously mentioned meta-analysis of studies with both proximal and distal strictures [108] did not find any significant difference in the rate of AEs between the two groups (OR 0.53, 95%CI 0.14–2.05); overall, the number of AEs was low, allowing both techniques to be considered safe to perform. However, two cases with severe AEs including bleeding and perforation have been described in the setting of intraductal biopsies [127,128], so the panel calls for cautious implementation by experienced physicians only, especially when considering that proximal strictures may be more difficult to approach, requiring higher technical skills to manipulate and advance the biopsy forceps.

3.3.3 Cost-effectiveness profile

One cost-utility analysis comparing five different sampling techniques among patients with suspected CCA and PSC did not reveal any significant difference between brushing and biopsy forceps sampling in terms of incremental QALYs and cost [129]. However, one could reasonably assume that, when both modalities are combined, it could lead to an increased procedural cost.

3.3.4 Environmental impact

It is known that processing of biopsy/cytology samples obtained during endoscopy leads to high greenhouse gas emissions; however, this is an unavoidable process. Despite the fact that combining two sampling modalities (brushing and biopsy forceps) in cases of proximal biliary strictures would definitely increase the environmental impact of the procedure as two devices and two specimen pots should be used, one cannot oversee the potential benefit of avoiding a second ERCP following a positive result after combining the two methods. Therefore, appropriate patient selection after evaluation by cross-sectional imaging remains crucial for minimizing the environmental impact of the procedure [87,130].

3.3.5 Certainty of evidence

The risk of bias assessment for each study can be found in **Table 16s**. The certainty of evidence for all clinical outcomes in this PICO question was downgraded owing to the fact that there were only observational studies included (**Table 5s**). Therefore, the panel concluded by making a conditional recommendation with a low quality of evidence.

RECOMMENDATION 7

ESGE suggests EUS-TA for perihilar strictures when ERCP-based modalities yield insufficient results, provided that curative resection is not feasible and/or when cross-sectional imaging has shown accessible extraluminal disease.

Conditional recommendation, low quality of evidence.

The combination of ERCP-based brush cytology and forceps biopsies provides high specificity in the diagnosis of perihilar strictures, but may yield insufficient results in a significant proportion of patients, culminating in a low diagnostic sensitivity. EUS-TA has proven useful in increasing the diagnostic yield. Although it is regarded as safe with low overall complication rates (<1%) and carries a low risk of bile leakage during EUS-FNA for biliary strictures (2.6%) [131], some specific considerations apply to patients with perihilar disease.

3.3.6 Benefits

A single-blinded comparative study confirmed superior sensitivity and diagnostic accuracy for EUS-FNA in suspected malignant biliary strictures, compared with ERCP-based brush cytology + forceps biopsies (94% and 94% vs. 50% and 53%, respectively) [79], results that are in line with more recent studies on the topic [76, 132]. In the context of perihilar disease in particular, one of the first prospective studies evaluating the yield of EUS-FNA in surgical patients with negative brush cytology ($n = 44$) was published in 2004 and showed high diagnostic accuracy (91%) and sensitivity (89%) [133]. Most importantly, EUS and EUS-FNA changed the surgical approach in almost two-thirds of patients, without resulting in complications.

When comparing the diagnostic accuracy of EUS-TA in perihilar and distal strictures however, significant differences in sensitivity and negative predictive value have surfaced. A 2020 prospective evaluation of EUS-FNA in the diagnosis of biliary strictures ($n = 97$; 46% hilar) showed an overall sensitivity of 75% (95%CI 64%–84%), with subgroup sensitivity and negative predictive value reaching 95% and 93% for distal lesions without stenting, but being much lower (56% and 33%, respectively) in patients with stented perihilar lesions [134]. While it should be noted that only early generation 22–25G FNA needles were used in this study, hilar location, underlying PSC, and previous stenting were all identified as independent risk factors for inaccurate histologic diagnosis using EUS-TA.

Lower EUS-FNA sensitivity in proximal CCA has been reproduced in several studies. Differences in tumor biology, absence in hypoechogenic mass-like appearance, and diffuse axial growth patterns may complicate successful identification of the proximal lesion itself [135, 136]. Although no comparisons between distal and proximal strictures exist to date, it has been suggested that contrast-enhanced harmonic EUS might increase T-staging adequacy [132, 137]. A previous meta-analysis [138] found a 15% (95%CI 9%–24%) incremental benefit of EUS after inconclusive ERCP with brushing; however, in this study, patients with both proximal and distal strictures were included. Moreover, in a recent meta-analysis of 11 studies including patients with both perihilar and proximal strictures, the pooled sensitivity of ERCP alone with any tissue acquisition method and EUS alone did not differ (70% [95%CI 66%–73%] vs. 74% [71%–77%]; $P = 0.31$) [139].

The studies evaluating the role of EUS in the diagnosis of perihilar strictures are presented in **Table 17s**. The pooled rates of sensitivity and diagnostic accuracy were 78% (95%CI 70%–86%; $I^2 = 76\%$) and 84% (95%CI 78%–91%; $I^2 = 46\%$), respectively. The task force identified only two comparative studies [76, 77] that

compared EUS-TA and ERCP with brush cytology for patients with perihilar strictures. The meta-analysis of these two studies showed an incremental diagnostic yield for adding EUS-TA to ERCP of 33% (95%CI 15%–50%; $P < 0.001$; $I^2 = 0\%$) (**Fig. 8s**).

3.3.7 Harms

Peritoneal seeding and subsequent iatrogenic upstaging are theoretical, yet clinically significant, limitations of EUS-TA and should be weighed against their potential diagnostic benefit. Even more so, EUS-TA for CCA has been wielded as a contraindication for liver transplantation [135]. The clear majority of published cases are however limited to needle tract recurrences in the context of pancreatic adenocarcinoma [140] or following radiofrequency ablation for hepatic lesions [141]. A Japanese nationwide survey suggested an incidence rate of 0.33% in the context of PDAC, with a significantly higher rate of needle tract recurrences in patients with PDAC who had undergone transgastric EUS-TA (0.86%) [142]. A pattern that might be explained by the needle tract location lying beyond the surgical resection margins.

Several retrospective series have evaluated the risk of peritoneal carcinomatosis following EUS-FNA in the context of PDAC, where it seems to outperform percutaneous FNA (2% vs. 16%) [143] and no differences were seen when comparing EUS-FNA with alternative methods of tissue acquisition [144, 145]. A recent meta-analysis of 10 studies (13 238 patients) showed that the pooled rate of needle tract seeding after EUS-TA of pancreatic lesions was 0.3% (95%CI 0.2%–0.4%) and no difference was observed in terms of metachronous peritoneal dissemination between patients who underwent EUS-TA and nonsampled patients (OR 1.0, 95%CI 0.7–1.5; $P = 0.31$), thereby confirming the low risk of seeding with this procedure [146].

Little evidence on EUS-TA-related peritoneal seeding is available in hilar CCA, with one specifically designed retrospective study ($n = 150$) showing no significant impact of needle passes on overall or progression-free survival [147]. A comparative study in patients with CCA undergoing transperitoneal FNA before neoadjuvant chemoradiotherapy and liver transplantation showed higher rates of peritoneal metastasis (83%) in patients with a positive transperitoneal FNA [148]. The risk of needle tract seeding seems higher however following a percutaneous approach than with EUS [143], making application of these recommendations to EUS-TA more difficult.

While data on exclusively proximal strictures are lacking, a recent meta-analysis of studies with both proximal and distal strictures showed that EUS-TA was associated with significantly fewer AEs compared with ERCP-based sampling (OR 8.1, 95%CI 3.0–22.3), with minor bleeding being the main EUS-associated AE [139].

3.3.8 Cost-effectiveness profile

While the cost of EUS with FNA/FNB varies across Europe depending on the local market, ERCP resulted in 9.05 QALYs and a cost of \$34 685, for a cost-effectiveness ratio of \$3832, while EUS resulted in an incremental increase of 0.13 QALYs and \$2773, for an incremental cost-effectiveness ratio (ICER) of \$20 840 per QALY gained [40].

3.3.9 Environmental impact

There are no data about the potential environmental footprint of EUS-TA for proximal strictures; however, the ecologic burden of an additional procedure should be taken into account (endoscope reprocessing, use of FNA/FNB, sample processing, and other aspects). Furthermore, as for every endoscopic procedure, the presence of an appropriate indication to avoid unnecessary examinations should be recorded prior to the examination [88].

3.3.10 Certainty of evidence

The risk of bias assessment for each study can be found in **Table 18s**. The certainty of evidence for all clinical outcomes in this PICO question was downgraded owing to the fact that there were only observational studies included (**Table 5s**). Therefore, the panel concluded by making a conditional recommendation with a low quality of evidence.

3.4 Intraductal Imaging

RECOMMENDATION 8

ESGE suggests using standard ERCP diagnostic modalities at index ERCP. In the case of indeterminate biliary strictures, ESGE suggests taking cholangioscopy-guided biopsies, in addition to the standard ERCP diagnostic modalities. Additional intraductal biliary imaging modalities can be selectively used, based on clinical context, local expertise, and resource availability. Conditional recommendation, very low quality of evidence.

The interpretation of real-time images during cholangioscopy may aid in distinguishing between benign and malignant strictures. Malignant lesions typically appear as either nodular, papillary, or infiltrating masses. Nodular masses usually lead to luminal obstruction and exhibit irregular mucosa with pronounced neovascularization. Papillary masses, on the other hand, feature numerous papillary projections and less neovascularization, while infiltrating masses cause luminal narrowing without a distinct mass, but display more whitish mucosal discoloration and neovascularization [149].

The documented sensitivity of visual assessment for identifying malignancy in strictures varies from 64% to 95% [149, 150], with most evidence on cholangioscopy being derived from clinical experiences with single-operator cholangioscopy (SOC). In fact, while other cholangioscopy methods, such as direct cholangioscopy and the dual-operator mother–baby technique, may be employed selectively depending on the clinical scenario, local proficiency, and resource availability, SOC should be regarded as the preferred technique for cholangioscopy (**Table 19s**). In terms of visual assessment performance, image quality has improved over the last few years, and artificial intelligence-based systems have been specifically trained with SOC images [151, 152], potentially enabling the avoidance of significant interobserver variation, and/or targeting biopsies. Nevertheless, further study is required to assess the utility

of artificial intelligence before a recommendation can be issued.

Endoscopic impressions alone are therefore not considered a recognized standard for making oncologic or other critical decisions. The primary utility of cholangioscopy lies in tissue acquisition; however, recognizing the distinguishing features of malignant strictures can facilitate the targeting of cholangioscopy-guided biopsies, potentially enhancing the diagnostic efficacy of this technique.

Alternative methods for assessing biliary strictures, including intraductal ultrasound (IDUS) and confocal laser endomicroscopy (CLE), are still evolving and have not established a concrete role in clinical practice. IDUS findings suggestive of malignancy include eccentric wall thickening, destruction of wall layers, intraluminal mass with irregular margins possibly invading surrounding tissue, and heterogeneous lesions with uneven mucosal surfaces [152,153,154]. Similarly, CLE employs slender confocal laser probes inserted through the duodenoscope's working channel, and malignant strictures manifest as thick dark bands of collagen fibrils and thickened white bands within vessels [155]. Both IDUS and CLE have been shown to improve sensitivity in diagnosing malignant strictures when compared with ERCP alone; however, these procedures are costly and require considerable skill to master, with an anticipated low level of interobserver agreement, thereby impeding their widespread adoption in the near future.

3.4.1 Benefits

Focusing on cholangioscopy, our de novo literature search identified 12 studies (including one RCT) (**Table 20s**) assessing the diagnostic performances of standard ERCP diagnostic modalities, including fluoroscopy-guided biopsies with/without brush cytology, compared with ERCP with cholangioscopy [80, 156,157,158].

The analysis revealed that the incremental yield of cholangioscopy-guided biopsies was 27% (95%CI 10%–45%), with a significant superiority compared with standard ERCP ($P=0.002$; $I^2=62\%$) (**Fig. 9s**). Furthermore, the sensitivity of ERCP with cholangioscopy was notably higher than standard ERCP (74% [95%CI 62%–86%] vs. 50% [28%–72%]; OR 1.1, 95%CI 1.0–1.3; $I^2=64\%$) (**Fig. 10s**). In the case of biliary strictures of undetermined etiology despite previous ERCP with standard diagnostic modalities (indeterminate biliary strictures), given the incremental sensitivity yield, patients should be referred to specialized tertiary centers for cholangioscopy.

3.4.2 Harms

In our meta-analysis, no disparities between cholangioscopy and standard ERCP were found in terms of risk of AEs (OR 1.5, 95%CI 0.8–2.5; $I^2=0\%$) (**Fig. 11s**), with pancreatitis and cholangitis being the most frequently reported. In this regard, the evidence regarding the potential benefits of antibiotic prophylaxis for preventing post-endoscopy cholangitis in cholangioscopy is limited, retrospective, and conflicting [159,160,161,162,163]. Of note, one study reported that the additional time required for cholangioscopy during ERCP was around 14 minutes (95%CI 10–20 minutes) [157]. Moreover, access to cholan-

gioscopy remains largely confined to tertiary referral centers with endoscopists specifically trained in intraductal biliary imaging modalities.

3.4.3 Cost-effectiveness profile

One study detected an additional expense of \$2637 when incorporating cholangioscopy into ERCP [164]; however, it has been shown that, in selected cases, cholangioscopy yields cost-effective outcomes, reducing the need for multiple procedures and associated expenses in diagnosing malignancies. In fact, when assessing the economic ramifications of endoscopy procedures and hospital admissions necessary for the diagnosis and management of indeterminate biliary strictures, with and without the use of SOC, the implementation of cholangioscopy demonstrated cost-effectiveness, resulting in a reduction in both the number of procedures (relative reduction of 31%) and associated costs (decrease of €13000, representing a relative variation of 5%) when compared with standard ERCP [164].

3.4.4 Environmental impact

There are no data about the potential environmental footprint of cholangioscopy for biliary strictures. Waste production derived from the use of disposable devices and endoscopes (i.e. single-use cholangioscopes) is one of the main sources of direct carbon emissions in endoscopy [165]. Therefore, combining cholangioscopy with standard ERCP would increase the environmental impact of the procedure. Moreover, an adjunctive sampling modality (cholangioscopy-guided biopsies) would translate into further increases in the indirect sources of emissions derived from processing of histologic samples. On the other hand, the incremental sensitivity yield of cholangioscopy compared with standard ERCP may lead to a reduction in the number of unnecessary re-examinations, with theoretical benefit in terms of avoiding procedure-related sources of direct carbon emission, and indirect sources such as unnecessary patient transportation [87].

3.4.5 Certainty of the evidence

The risk of bias assessment for each study can be found in **Table 21s**. The certainty of evidence for all clinical outcomes in this PICO question was downgraded because it was based mainly on nonrandomized studies (**Table 5s**). For the two outcomes of incremental yield and AE rate, further downgrading was applied owing to indirectness (heterogeneity in the standard ERCP modalities for tissue sampling), so downgrading the quality of evidence to very low.

4 Unmet needs and evidence gaps

The ESGE commissioned this guideline on diagnostic work-up of biliary strictures to facilitate the appraisal of the published evidence on tumor markers, distal and perihilar strictures, and intraductal imaging to provide recommendations and compact, up-to-date literature to support the statements. Unfortunately, most of the literature is based mainly on the use of the diagnostic techniques for pancreatic masses, and isolated data

on biliary stricture are scarce and frequently based on subgroup analyses of other studies.

As is evident above, the majority of the recommendations in this Guideline are based on low quality evidence owing to the lack of RCTs on these topics. The low quality of the evidence points to the pressing need for prospective studies and RCTs in this field. Various unmet needs, such as for distal stricture (data on third generation, end-cutting EUS-FNB needles for tissue acquisition) and for perihilar stricture (data on EUS-FNB versus cholangioscopy-guided biopsies), still need to be addressed in the literature. More data are also needed about methods to improve and implement the handling of cytopathology after tissue sampling, and about the addition of more advanced techniques such as next generation sequencing in this field. Liquid biopsies and the analysis of portal vein circulating cells potentially represent interesting research fields that need to be further developed and investigated, given the promising preliminary results. Moreover, in recent times, artificial intelligence has forged its way into routine endoscopy practice, and studies to incorporate its use for the diagnosis of biliary stricture are scarce. Furthermore, the role of green endoscopy, including the impact of imaging and use of endoscopy equipment on the environment, is another uncovered area in this topic.

Disclaimer

ESGE Guidelines represent a consensus of best practice based on the available evidence at the time of preparation. They may not apply to all situations and should be interpreted in the setting of specific clinical scenarios and resource availability. They are intended to be an educational tool to provide information that may support endoscopists in providing care to patients.

They are not rules and should not be used either to replace clinical judgement or to establish a legal standard of care.

Acknowledgement

We thank Professors Andrea Anderloni and Ioannis S. Papanikolaou for their thorough review of the draft of this manuscript.

Conflict of Interest

M. Arvanitakis has received lecture fees from Boston Scientific (2024 ongoing). M. Bronswijk's department has received trial support from Boston Scientific (2021 ongoing). T. Beyna has received consultancy and lecture fees from Olympus, Boston Scientific, and MicroTech, and lecture fees from Cook (all ongoing); his department has received research support/grants from Olympus, Boston Scientific, MicroTech, and Cook. M. Ellrichmann has received consultancy fees from Boston Scientific (2015 ongoing) and MicroTech (2023 ongoing). I. Hritz has received consultancy and training fees from Olympus (2018 ongoing) and consultancy and speaker's fees from MicroTech (2023 ongoing). M. Spadaccini has received speaker's fees from Boston Scientific (2023–2024). G.J.M. Webster has received support for teaching (2010–2024). S.F. Crinò, J. Dhar, A. Facciorusso, R. Gincul, P. Gkolfakis, L. Kylänpää, B. Martinez-Moreno, M. Pezzullo, M. Rimbis, J. Samanta, K. Triantafyllou, R.L.J. van Wanrooij declare that they have no conflicts of interest.

References

- [1] Pouw RE, Barret M, Biermann K et al. Endoscopic tissue sampling – Part 1: Upper gastrointestinal and hepatopancreatobiliary tracts. European Society of Endoscopy (ESGE) Guideline. *Endoscopy* 2021; 53: 1174–1188 doi:10.1055/a-16111-5091
- [2] Guyatt G, Oxman AD, Akl EA et al. GRADE guidelines: 1. Introduction-GRADE evidence profiles and summary of findings tables. *J Clin Epidemiol* 2011; 64: 383–394 doi:10.1016/j.jclinepi.2010.04.026
- [3] Dumonceau JM, Hassan C, Riphaus A et al. European Society of Gastrointestinal Endoscopy (ESGE) Guideline Development Policy. *Endoscopy* 2012; 44: 626–629 doi:10.1055/s-0031-1291747
- [4] Dhar J, Gupta P, Samanta J. The role of endoscopy in malignant hilar obstruction. *Ann Gastroenterol* 2023; 36: 347–359 doi:10.20524/aog.2023.0810
- [5] Nabi Z, Reddy DN. Multidisciplinary approach to indeterminate biliary strictures. *Gastrointest Endosc Clin N Am* 2022; 32: 411–425 doi:10.1016/j.giec.2022.01.004
- [6] Singh A, Gelrud A, Agarwal B. Biliary strictures: diagnostic considerations and approach. *Gastroenterol Rep (Oxf)* 2015; 3: 22–31 doi:10.1093/gastro/gou072
- [7] Tirotta F, Giovinnazzo F, Hodson J et al. Risk factors to differentiate between benign proximal biliary strictures and perihilar cholangiocarcinoma. *HPB (Oxford)* 2020; 22: 1753–1758
- [8] Katabathina VS, Dasyam AK, Dasyam N et al. Adult bile duct strictures: role of MR imaging and MR cholangiopancreatography in characterization. *Radiographics* 2014; 34: 565–586 doi:10.1148/rq.343125211
- [9] Inui K, Yoshino J, Miyoshi H. Differential diagnosis and treatment of biliary strictures. *Clin Gastroenterol Hepatol* 2009; 7: S79–S83 doi:10.1016/j.cgh.2009.08.027
- [10] Carpelan-Holmstrom M, Louhimo J, Stenman UH et al. CEA, CA 19–9 and CA 72–4 improve the diagnostic accuracy in gastrointestinal cancers. *Anticancer Res* 2002; 22: 2311–2316
- [11] Ni XG, Bai XF, Mao YL et al. The clinical value of serum CEA, CA19–9, and CA242 in the diagnosis and prognosis of pancreatic cancer. *Eur J Surg Oncol* 2005; 31: 164–169 doi:10.1016/j.ejso.2004.09.007
- [12] Ballehaninna UK, Chamberlain RS. The clinical utility of serum CA 19–9 in the diagnosis, prognosis and management of pancreatic adenocarcinoma: An evidence based appraisal. *J Gastrointest Oncol* 2012; 3: 105–119 doi:10.3978/j.issn.2078-6891.2011.021
- [13] Lee T, Teng TZJ, Shelat VG. Carbohydrate antigen 19–9 - tumor marker: Past, present, and future. *World J Gastrointest Surg* 2020; 12: 468–490 doi:10.4240/wjgs.v12.i12.468
- [14] Sachan A, Saluja SS, Nekarakanti PK et al. Raised CA19–9 and CEA have prognostic relevance in gallbladder carcinoma. *BMC Cancer* 2020; 20: 826
- [15] Meng Q, Shi S, Liang C et al. Diagnostic and prognostic value of carcinoembryonic antigen in pancreatic cancer: a systematic review and meta-analysis. *Onco Targets Ther* 2017; 10: 4591–4598 doi:10.2147/OTT.S145708
- [16] Luo G, Jin K, Deng S et al. Roles of CA19–9 in pancreatic cancer: Biomarker, predictor and promoter. *Biochim Biophys Acta Rev Cancer* 2021; 1875: 188409 doi:10.1016/j.bbcan.2020.188409
- [17] Marrelli D, Caruso S, Pedrazzani C et al. CA19–9 serum levels in obstructive jaundice: clinical value in benign and malignant conditions. *Am J Surg* 2009; 198: 333–339 doi:10.1016/j.amjsurg.2008.12.031
- [18] Juntermanns B, Radunz S, Heuer M et al. Tumor markers as a diagnostic key for hilar cholangiocarcinoma. *Eur J Med Res* 2010; 15: 357–361 doi:10.1186/2047-783x-15-8-357
- [19] Qin XL, Wang ZR, Shi JS et al. Utility of serum CA19–9 in diagnosis of cholangiocarcinoma: in comparison with CEA. *World J Gastroenterol* 2004; 10: 427–432
- [20] Paganuzzi M, Onetto M, Marroni P et al. CA 19–9 and CA 50 in benign and malignant pancreatic and biliary diseases. *Cancer* 1988; 61: 2100–2108 doi:10.1002/1097-0142(19880515)61:10<2100::aid-cnrcr2820611028>3.0.co;2-z
- [21] Morris-Stiff G, Teli M, Jardine N et al. CA19–9 antigen levels can distinguish between benign and malignant pancreaticobiliary disease. *Hepatobiliary Pancreat Dis Int* 2009; 8: 620–626
- [22] Sandanayake NS, Sinclair J, Andreola F et al. A combination of serum leucine-rich alpha-2-glycoprotein 1, CA19–9 and interleukin-6 differentiate biliary tract cancer from benign biliary strictures. *Br J Cancer* 2011; 105: 1370–1378
- [23] Barroso Marquez L, Chao Gonzalez L, Samada Suarez M et al. Endoscopic retrograde cholangiopancreatography and carbohydrate antigen 19–9 in the differential diagnosis of biliary strictures. *Rev Esp Enferm Dig* 2022; 114: 204–207
- [24] Ikuta S, Aihara T, Nakajima T et al. Preoperative alkaline phosphatase-adjusted CA19–9 as a superior prognosticator for extrahepatic biliary tract cancer with jaundice. *Cancer Diagn Progn* 2022; 2: 569–575
- [25] Sakamoto K, Haga Y, Yoshimura R et al. Comparative effectiveness of the tumour diagnostics, CA 19–9, CA 125 and carcinoembryonic antigen in patients with diseases of the digestive system. *Gut* 1987; 28: 323–329
- [26] Natsios A, Vezakis A, Kaparos G et al. Significance of serum and bile tumor markers in the diagnostic approach of patients with malignant pancreatobiliary disease. *J BUON* 2015; 20: 1030–1036
- [27] Kim MS, Jeon TJ, Park JY et al. Clinical interpretation of elevated CA 19–9 levels in obstructive jaundice following benign and malignant pancreatobiliary disease. *Korean J Gastroenterol* 2017; 70: 96–102 doi:10.4166/kjg.2017.70.2.96
- [28] Lindberg B, Arnelo U, Bergquist A et al. Diagnosis of biliary strictures in conjunction with endoscopic retrograde cholangiopancreatography, with special reference to patients with primary sclerosing cholangitis. *Endoscopy* 2002; 34: 909–916
- [29] Ince AT, Yildiz K, Baysal B et al. Roles of serum and biliary CEA, CA19–9, VEGFR3, and TAC in differentiating between malignant and benign biliary obstructions. *Turk J Gastroenterol* 2014; 25: 162–169
- [30] Budzynska A, Nowakowska-Dulawa E, Marek T et al. Differentiation of pancreatobiliary cancer from benign biliary strictures using neutrophil gelatinase-associated lipocalin. *J Physiol Pharmacol* 2013; 64: 109–114
- [31] Ohara H, Nakazawa T, Kawa S et al. Establishment of a serum IgG4 cut-off value for the differential diagnosis of IgG4-related sclerosing cholangitis: a Japanese cohort. *J Gastroenterol Hepatol* 2013; 28: 1247–1251 doi:10.1111/jgh.12248
- [32] Boonstra K, Culver EL, de Buy Wenniger LM et al. Serum immunoglobulin G4 and immunoglobulin G1 for distinguishing immunoglobulin G4-associated cholangitis from primary sclerosing cholangitis. *Hepatology* 2014; 59: 1954–1963
- [33] Kim HJ, Kim MH, Myung SJ et al. A new strategy for the application of CA19–9 in the differentiation of pancreaticobiliary cancer: analysis using a receiver operating characteristic curve. *Am J Gastroenterol* 1999; 94: 1941–1946 doi:10.1111/j.1572-0241.1999.01234.x
- [34] Ong SL, Sachdeva A, Garcea G et al. Elevation of carbohydrate antigen 19.9 in benign hepatobiliary conditions and its correlation with serum bilirubin concentration. *Dig Dis Sci* 2008; 53: 3213–3217
- [35] Vestergaard EM, Hein HO, Meyer H et al. Reference values and biological variation for tumor marker CA 19–9 in serum for different

- Lewis and secretor genotypes and evaluation of secretor and Lewis genotyping in a Caucasian population. *Clin Chem* 1999; 45: 54–61
- [36] Kamisawa T, Nakazawa T, Tazuma S et al. Clinical practice guidelines for IgG4-related sclerosing cholangitis. *J Hepatobiliary Pancreat Sci* 2019; 26: 9–42 doi:10.1002/jhbp.596
- [37] Oseini AM, Chaiteerakij R, Shire AM et al. Utility of serum immunoglobulin G4 in distinguishing immunoglobulin G4-associated cholangitis from cholangiocarcinoma. *Hepatology* 2011; 54: 940–948
- [38] Mendes FD, Jorgensen R, Keach J et al. Elevated serum IgG4 concentration in patients with primary sclerosing cholangitis. *Am J Gastroenterol* 2006; 101: 2070–2075
- [39] Wilson C, Ebling R, Henig C et al. Significant, quantifiable differences exist between IgG subclass standards WHO67/97 and ERM-DA470k and can result in different interpretation of results. *Clin Biochem* 2013; 46: 1751–1755
- [40] Oliver JB, Burnett AS, Ahlawat S et al. Cost-effectiveness of the evaluation of a suspicious biliary stricture. *J Surg Res* 2015; 195: 52–60 doi:10.1016/j.jss.2014.12.037
- [41] Nowak PM, Bis A, Rusin M et al. Carbon footprint of the analytical laboratory and the three-dimensional approach to its reduction. *Green Anal Chem* 2023; 4: 100051
- [42] Elmunzer BJ, Maranki JL, Gomez V et al. ACG Clinical Guideline: Diagnosis and management of biliary strictures. *Am J Gastroenterol* 2023; 118: 405–426 doi:10.14309/ajg.0000000000002190
- [43] Qumseya BJ, Jamil LH, Elmunzer BJ et al. ASGE guideline on the role of endoscopy in the management of malignant hilar obstruction. *Gastrointest Endosc* 2021; 94: 222–234 e222 doi:10.1016/j.gie.2020.12.035
- [44] Lalani T, Couto CA, Rosen MP et al. ACR appropriateness criteria jaundice. *J Am Coll Radiol* 2013; 10: 402–409 doi:10.1016/j.jacr.2013.02.020
- [45] Johnson KD, Perisetti A, Tharian B et al. Endoscopic retrograde cholangiopancreatography-related complications and their management strategies: a "scoping" literature review. *Dig Dis Sci* 2020; 65: 361–375
- [46] Magnuson TH, Bender JS, Duncan MD et al. Utility of magnetic resonance cholangiography in the evaluation of biliary obstruction. *J Am Coll Surg* 1999; 189: 63–71 discussion 71–62
- [47] Singh A, Mann HS, Thukral CL et al. Diagnostic accuracy of MRCP as compared to ultrasound/CT in patients with obstructive jaundice. *J Clin Diagn Res* 2014; 8: 103–107
- [48] Rosch T, Meining A, Fruhmorgen S et al. A prospective comparison of the diagnostic accuracy of ERCP, MRCP, CT, and EUS in biliary strictures. *Gastrointest Endosc* 2002; 55: 870–876 doi:10.1067/mge.2002.124206
- [49] Jayamohan AE, Jean A, Lakshmanan PM et al. The radiological study to establish the accuracy of MRCP over USG & CT in diagnosing the case of obstructive jaundice. *Asian J Med Radiol Res* 2019; 7: 46–51
- [50] Jena P, Misra AP, Jena D. To establish the accuracy of MRCP over USG & CT in diagnosing the case of obstructive Jaundice with radiological study. *Int J Radiol Diagn Imaging* 2021; 4: 133–136
- [51] Upadhyaya V, Upadhyaya DN, Ansari MA et al. Comparative assessment of imaging modalities in biliary obstruction. *Indian J Radiol Imaging* 2006; 16: 577–582
- [52] Rao M, Chaudhary P, Arora MP et al. A prospective comparative study of the role of CT and MRI-MRCP in the preoperative assessment of obstructive jaundice and their intraoperative corroboration. *Hellenic J Surg* 2014; 86: 19–25
- [53] Singh SS, Shafi F, Singh NR. Comparative study of multidetector computed tomography and magnetic resonance cholangiopancreatography in obstructive jaundice. *J Med Soc* 2017; 31: 162–168
- [54] Saluja SS, Sharma R, Pal S et al. Differentiation between benign and malignant hilar obstructions using laboratory and radiological investigations: a prospective study. *HPB (Oxford)* 2007; 9: 373–382
- [55] Salam F Islam NF, Nazmul HM et al. Comparison among the role of different imaging techniques in diagnosis of malignant lesions causing obstructive jaundice. *J Bangladesh Coll Phys Surg* 2021; 39: 233–240
- [56] Iron P, Shetty P, Aggarwal A. Diagnostic utility of MRCP in obstructive jaundice and comparison with CT & ultrasonography. *Int J Radiol Diagn Imaging* 2022; 5: 1–6
- [57] Raguraman P. MRI combined with MRCP versus helical CT in evaluation of patients with obstructive jaundice. *Int J Recent Sci Res* 2015; 6: 3642–3650
- [58] Khalid MS Arooj S, Ahmed A et al. Diagnostic accuracy of ultrasound sonography test and computed tomography compared with magnetic resonance cholangio pancreatography in patients with obstructive jaundice considering endoscopic retrograde cholangio pancreatography as gold standard. *J Postgrad Med Inst* 2023; 37: 201–207
- [59] Makhlof M, Soltan H, Ammar M et al. Value of magnetic resonance cholangiopancreatography prior to endoscopic retrograde cholangiopancreatography in ultrasonographically and laboratory diagnosed obstructive jaundice. *Egypt J Surgery* 2021; 40: 153–159
- [60] Expert Panel on Gastrointestinal I. Hindman NM, Arif-Tiwari H et al. ACR Appropriateness Criteria Jaundice. *J Am Coll Radiol* 2019; 16: S126–S140
- [61] Kaltenthaler EC, Walters SJ, Chilcott J et al. MRCP compared to diagnostic ERCP for diagnosis when biliary obstruction is suspected: a systematic review. *BMC Med Imaging* 2006; 6: 9
- [62] Mendler MH, Bouillet P, Sautereau D et al. Value of MR cholangiography in the diagnosis of obstructive diseases of the biliary tree: a study of 58 cases. *Am J Gastroenterol* 1998; 93: 2482–2490 doi:10.1111/j.1572-0241.1998.00708.x
- [63] Guibaud L, Bret PM, Reinhold C et al. Bile duct obstruction and choledocholithiasis: diagnosis with MR cholangiography. *Radiology* 1995; 197: 109–115
- [64] Macaulay SE, Schulte SJ, Sekijima JH et al. Evaluation of a non-breath-hold MR cholangiography technique. *Radiology* 1995; 196: 227–232 doi:10.1148/radiology.196.1.17784572
- [65] Romagnuolo J, Bardou M, Rahme E et al. Magnetic resonance cholangiopancreatography: a meta-analysis of test performance in suspected biliary disease. *Ann Intern Med* 2003; 139: 547–557 doi:10.7326/0003-4819-139-7-200310070-00006
- [66] US Food and Drug Administration. What are the radiation risks from CT. Accessed November 06, 2024; <https://www.fda.gov/radiation-emitting-products/medical-x-ray-imaging/what-are-radiation-risks-ct>
- [67] Berrington de Gonzalez A, Kim KP, Berg CD. Low-dose lung computed tomography screening before age 55: estimates of the mortality reduction required to outweigh the radiation-induced cancer risk. *J Med Screen* 2008; 15: 153–158
- [68] Howard K, Lord SJ, Speer A et al. Value of magnetic resonance cholangiopancreatography in the diagnosis of biliary abnormalities in postcholecystectomy patients: a probabilistic cost-effectiveness analysis of diagnostic strategies. *Int J Technol Assess Health Care* 2006; 22: 109–118 doi:10.1017/s0266462306050902
- [69] Vergel YB, Chilcott J, Kaltenthaler E et al. Economic evaluation of MR cholangiopancreatography compared to diagnostic ERCP for the investigation of biliary tree obstruction. *Int J Surg* 2006; 4: 12–19 doi:10.1016/j.ijsu.2006.01.007
- [70] Roletto A, Zanardo M, Bonfitto GR et al. The environmental impact of energy consumption and carbon emissions in radiology departments: a systematic review. *Eur Radiol Exp* 2024; 8: 35 doi:10.1186/s41747-024-00424-6

- [71] McAlister S, McGain F, Petersen M et al. The carbon footprint of hospital diagnostic imaging in Australia. *Lancet Reg Health West Pac* 2022; 24: 100459 doi:10.1016/j.lanwpc.2022.100459
- [72] Tummala P, Munigala S, Eloubeidi MA et al. Patients with obstructive jaundice and biliary stricture +/- mass lesion on imaging: prevalence of malignancy and potential role of EUS-FNA. *J Clin Gastroenterol* 2013; 47: 532–537
- [73] Navaneethan U, Njei B, Lourdasamy V et al. Comparative effectiveness of biliary brush cytology and intraductal biopsy for detection of malignant biliary strictures: a systematic review and meta-analysis. *Gastrointest Endosc* 2015; 81: 168–176 doi:10.1016/j.gie.2014.09.017
- [74] Sadeghi A, Mohamadnejad M, Islami F et al. Diagnostic yield of EUS-guided FNA for malignant biliary stricture: a systematic review and meta-analysis. *Gastrointest Endosc* 2016; 83: 290–298 e291 doi:10.1016/j.gie.2015.09.024
- [75] Jo JH, Cho CM, Jun JH et al. Same-session endoscopic ultrasound-guided fine needle aspiration and endoscopic retrograde cholangiopancreatography-based tissue sampling in suspected malignant biliary obstruction: A multicenter experience. *J Gastroenterol Hepatol* 2019; 34: 799–805 doi:10.1111/jgh.14528
- [76] Moura DTH, de Moura EGH, Matuguma SE et al. EUS-FNA versus ERCP for tissue diagnosis of suspected malignant biliary strictures: a prospective comparative study. *Endosc Int Open* 2018; 6: E769–E777 doi:10.1055/s-0043-123186
- [77] Sobhrakhshankhah E, Sohrabi M, Norouzi HR et al. Tissue sampling through endoscopic ultrasound-guided fine needle aspiration versus endoscopic retrograde cholangiopancreatographic brushing cytology technique in suspicious malignant biliary stricture. *Middle East J Dig Dis* 2021; 13: 294–301
- [78] Yeo SJ, Cho CM, Jung MK et al. Comparison of the diagnostic performances of same-session endoscopic ultrasound- and endoscopic retrograde cholangiopancreatography-guided tissue sampling for suspected biliary strictures at different primary tumor sites. *Korean J Gastroenterol* 2019; 73: 213–218 doi:10.4166/kjg.2019.73.4.213
- [79] Weilert F, Bhat YM, Binmoeller KF et al. EUS-FNA is superior to ERCP-based tissue sampling in suspected malignant biliary obstruction: results of a prospective, single-blind, comparative study. *Gastrointest Endosc* 2014; 80: 97–104 doi:10.1016/j.gie.2013.12.031
- [80] Onoyama T, Matsumoto K, Takeda Y et al. Endoscopic ultrasonography-guided fine needle aspiration for extrahepatic cholangiocarcinoma: a safe tissue sampling modality. *J Clin Med* 2019; 8: 417 doi:10.3390/jcm8040417
- [81] Chung HG, Chang JI, Lee KH et al. Comparison of EUS and ERCP-guided tissue sampling in suspected biliary stricture. *PLoS One* 2021; 16: e0258887 doi:10.1371/journal.pone.0258887
- [82] Mathew P, Kanni P, Gowda M et al. A comparative study of endoscopic ultrasound fine-needle aspiration (EUS-FNA) and endoscopic retrograde cholangiopancreatography (ERCP)-based brush cytology for tissue diagnosis in malignant biliary obstruction. *Cureus* 2022; 14: e30291 doi:10.7759/cureus.30291
- [83] Nguyen NQ, Schoeman MN, Ruzskiewicz A. Clinical utility of EUS before cholangioscopy in the evaluation of difficult biliary strictures. *Gastrointest Endosc* 2013; 78: 868–874 doi:10.1016/j.gie.2013.05.020
- [84] De Moura DTH, De Moura EGH, Bernardo WM et al. Endoscopic retrograde cholangiopancreatography versus endoscopic ultrasound for tissue diagnosis of malignant biliary stricture: Systematic review and meta-analysis. *Endosc Ultrasound* 2018; 7: 10–19 doi:10.4103/2303-9027.193597
- [85] Bang JY, Kirtane S, Krall K et al. In memoriam: Fine-needle aspiration, birth: Fine-needle biopsy: The changing trend in endoscopic ultrasound-guided tissue acquisition. *Dig Endosc* 2019; 31: 197–202 doi:10.1111/den.13280
- [86] Facciorusso A, Crino SF, Ramai D et al. Comparative diagnostic performance of different techniques for EUS-guided fine-needle biopsy sampling of solid pancreatic masses: a network meta-analysis. *Gastrointest Endosc* 2023; 97: 839–848 e835 doi:10.1016/j.gie.2023.01.024
- [87] Maida M, Vitello A, Shahini E et al. Green endoscopy, one step toward a sustainable future: Literature review. *Endosc Int Open* 2024; 12: E968–E980 doi:10.1055/a-2303-8621
- [88] Rodriguez de Santiago E, Dinis-Ribeiro M, Pohl H et al. Reducing the environmental footprint of gastrointestinal endoscopy: European Society of Gastrointestinal Endoscopy (ESGE) and European Society of Gastroenterology and Endoscopy Nurses and Associates (ES-GENA) Position Statement. *Endoscopy* 2022; 54: 797–826
- [89] Aslanian HR, Estrada JD, Rossi F et al. Endoscopic ultrasound and endoscopic retrograde cholangiopancreatography for obstructing pancreas head masses: combined or separate procedures? *J Clin Gastroenterol* 2011; 45: 711–713 doi:10.1097/MCG.0b013e3182045923
- [90] Camus M, Trouilloud I, Villacis AL et al. Effectiveness of combined endoscopic ultrasound-guided fine-needle aspiration biopsy and stenting in patients with suspected pancreatic cancer. *Eur J Gastroenterol Hepatol* 2012; 24: 1281–1287
- [91] Chu YL, Wang XF, Gao XZ et al. Endoscopic ultrasonography in tandem with endoscopic retrograde cholangiopancreatography in the management of suspected distal obstructive jaundice. *Eur J Gastroenterol Hepatol* 2013; 25: 455–459
- [92] Gorris M, van der Valk NP, Fockens P et al. Does same session EUS-guided tissue acquisition and ERCP increase the risk of pancreatitis in patients with malignant distal biliary obstruction? *HPB (Oxford)* 2022; 24: 1634–1641
- [93] Purnak T, El Hajjll, Sherman S et al. Combined versus separate sessions of endoscopic ultrasound and endoscopic retrograde cholangiopancreatography for the diagnosis and management of pancreatic ductal adenocarcinoma with biliary obstruction. *Dig Dis Sci* 2021; 66: 2786–2794
- [94] Vila JJ, Kutz M, Goni S et al. Endoscopic and anesthetic feasibility of EUS and ERCP combined in a single session versus two different sessions. *World J Gastrointest Endosc* 2011; 3: 57–61 doi:10.4253/wjge.v3.i3.57
- [95] Gornals JB, Moreno R, Castellote J et al. Single-session endosonography and endoscopic retrograde cholangiopancreatography for biliopancreatic diseases is feasible, effective and cost beneficial. *Dig Liver Dis* 2013; 45: 578–583 doi:10.1016/j.dld.2013.01.023
- [96] Chawla S, Trick WE, Gilkey S et al. Does cholecystectomy status influence the common bile duct diameter? A matched-pair analysis *Dig Dis Sci* 2010; 55: 1155–1160
- [97] De Angelis C, Marietti M, Bruno M et al. Endoscopic ultrasound in common bile duct dilatation with normal liver enzymes. *World J Gastrointest Endosc* 2015; 7: 799–805
- [98] Beyer G, Kasprovicz F, Hannemann A et al. Definition of age-dependent reference values for the diameter of the common bile duct and pancreatic duct on MRCP: a population-based, cross-sectional cohort study. *Gut* 2023; 72: 1738–1744 doi:10.1136/gutjnl-2021-326106
- [99] Chhoda A, Dawod S, Grimshaw A et al. Evaluation of diagnostic yield of EUS among patients with asymptomatic common bile duct dilatation: systematic review and meta-analysis. *Gastrointest Endosc* 2021; 94: 890–901 e898
- [100] Rana SS, Bhasin DK, Sharma V et al. Role of endoscopic ultrasound in evaluation of unexplained common bile duct dilatation on magnetic resonance cholangiopancreatography. *Ann Gastroenterol* 2013; 26: 66–70

- [101] Attila T, Faigel DO. Endoscopic ultrasound in patients over 80 years old. *Dig Dis Sci* 2011; 56: 3065–3071 doi:10.1007/s10620-011-1718-7
- [102] Bruno M, Brizzi RF, Mezzabotta L et al. Unexplained common bile duct dilatation with normal serum liver enzymes: diagnostic yield of endoscopic ultrasound and follow-up of this condition. *J Clin Gastroenterol* 2014; 48: e67–e70
- [103] Kaspy MS, Hassan GM, Paquin SC et al. An assessment of the yield of EUS in patients referred for dilated common bile duct and normal liver function tests. *Endosc Ultrasound* 2019; 8: 318–320 doi:10.4103/eus.eus_21_19
- [104] Sousa M, Fernandes S, Proenca L et al. Diagnostic yield of endoscopic ultrasonography for dilation of common bile duct of indeterminate cause. *Rev Esp Enferm Dig* 2019; 111: 757–759 doi:10.17235/reed.2019.6278/2019
- [105] Malik S, Kaushik N, Khalid A et al. EUS yield in evaluating biliary dilatation in patients with normal serum liver enzymes. *Dig Dis Sci* 2007; 52: 508–512
- [106] Oppong KW, Mitra V, Scott J et al. Endoscopic ultrasound in patients with normal liver blood tests and unexplained dilatation of common bile duct and or pancreatic duct. *Scand J Gastroenterol* 2014; 49: 473–480 doi:10.3109/00365521.2013.878745
- [107] ASGE Standards of Practice Committee, Khashab MA, Chithadi KV et al. Antibiotic prophylaxis for GI endoscopy. *Gastrointest Endosc* 2015; 81: 81–89
- [108] Fujii-Lau LL, Thosani NC, Al-Haddad M et al. American Society for Gastrointestinal Endoscopy guideline on role of endoscopy in the diagnosis of malignancy in biliary strictures of undetermined etiology: methodology and review of evidence. *Gastrointest Endosc* 2023; 98: 694–712 e698 doi:10.1016/j.gie.2023.06.007
- [109] Weber A, von Weyhern C, Fend F et al. Endoscopic transpapillary brush cytology and forceps biopsy in patients with hilar cholangiocarcinoma. *World J Gastroenterol* 2008; 14: 1097–1101
- [110] Kulaksiz H, Strnad P, Rompp A et al. A novel method of forceps biopsy improves the diagnosis of proximal biliary malignancies. *Dig Dis Sci* 2011; 56: 596–601 doi:10.1007/s10620-010-1535-4
- [111] Yamamoto K, Tsuchiya T, Itoi T et al. Evaluation of novel slim biopsy forceps for diagnosis of biliary strictures: Single-institutional study of consecutive 360 cases (with video). *World J Gastroenterol* 2017; 23: 6429–6436
- [112] Inoue T, Kitano R, Kobayashi Y et al. Assessing the diagnostic yield of controllable biopsy-forceps for biliary strictures. *Scand J Gastroenterol* 2018; 53: 598–603 doi:10.1080/00365521.2017.1409799
- [113] Jung ES, Park SW, Kim JH et al. Comparison of the diagnostic performance of novel slim biopsy forceps with conventional biopsy forceps for biliary stricture: a multicenter retrospective study. *J Pers Med* 2021; 11: 55
- [114] Kawashima H, Itoh A, Ohno E et al. Transpapillary biliary forceps biopsy to distinguish benign biliary stricture from malignancy: how many tissue samples should be obtained? *Dig Endosc* 2012; 24: 22–27
- [115] Mutignani M, Galasso D, Familiari P et al. Comparison of standard and jumbo endobiliary biopsy for histological diagnosis of hilar biliary strictures: interim report of a prospective randomized trial. *Gastrointest Endosc* 2008; 67: PAB169
- [116] Yoon SB, Moon SH, Ko SW et al. Brush cytology, forceps biopsy, or endoscopic ultrasound-guided sampling for diagnosis of bile duct cancer: a meta-analysis. *Dig Dis Sci* 2022; 67: 3284–3297 doi:10.1007/s10620-021-07138-4
- [117] Tappata M, McDonald NM, Abdallah M et al. Efficacy of wire-guided biopsy forceps for tissue sampling in endoscopic retrograde cholangiopancreatography: a preliminary experience. *Clin Endosc* 2023; 56: 527–530 doi:10.5946/ce.2022.152
- [118] Yamashita Y, Ueda K, Kawaji Y et al. The wire-grasping method as a new technique for forceps biopsy of biliary strictures: a prospective randomized controlled study of effectiveness. *Gut Liver* 2016; 10: 642–648 doi:10.5009/gnl15231
- [119] Lin LF, Siau CP, Ho KS et al. Guidewire technique for endoscopic transpapillary procurement of bile duct biopsy specimens without endoscopic sphincterotomy. *Gastrointest Endosc* 2003; 58: 272–274
- [120] Higashizawa T, Tamada K, Tomiyama T et al. Biliary guidewire facilitates bile duct biopsy and endoscopic drainage. *J Gastroenterol Hepatol* 2002; 17: 332–336 doi:10.1046/j.1440-1746.2002.02691.x
- [121] Porner D, Kaczmarek DJ, Helling D et al. Transpapillary tissue sampling of biliary strictures: balloon dilatation prior to forceps biopsy improves sensitivity and accuracy. *Sci Rep* 2020; 10: 17423 doi:10.1038/s41598-020-74451-9
- [122] de Bellis M, Fogel EL, Sherman S et al. Influence of stricture dilation and repeat brushing on the cancer detection rate of brush cytology in the evaluation of malignant biliary obstruction. *Gastrointest Endosc* 2003; 58: 176–182 doi:10.1067/mge.2003.345
- [123] Karsenti D, Privat J, Charissoux A et al. Multicenter randomized trial comparing diagnostic sensitivity and cellular abundance with aggressive versus standard biliary brushing for bile duct stenosis without mass syndrome. *Endoscopy* 2023; 55: 796–803
- [124] Gorris M, van Huijgevoort NCM, Fockens P et al. Comparison of two intraductal brush cytology devices for suspected malignant biliary strictures: randomized controlled trial. *Surg Endosc* 2023; 37: 4566–4573 doi:10.1007/s00464-023-09916-9
- [125] Kylanpää L, Boyd S, Ristimäki A et al. A prospective randomised study of dense Infinity cytological brush versus regularly used brush in pancreaticobiliary malignancy. *Scand J Gastroenterol* 2016; 51: 590–593 doi:10.3109/00365521.2015.1121514
- [126] Wang J, Xia M, Jin Y et al. More endoscopy-based brushing passes improve the detection of malignant biliary strictures: a multicenter randomized controlled trial. *Am J Gastroenterol* 2022; 117: 733–739 doi:10.14309/ajg.0000000000001666
- [127] Pugliese V, Antonelli G, Vincenti M et al. Endoductal tissue sampling of biliary strictures through endoscopic retrograde cholangiogram creatography (ERCP). *Tumori* 1997; 83: 698–702
- [128] Schoefl R, Haefner M, Wrba F et al. Forceps biopsy and brush cytology during endoscopic retrograde cholangiopancreatography for the diagnosis of biliary stenoses. *Scand J Gastroenterol* 1997; 32: 363–368
- [129] Njei B, McCarty TR, Varadarajulu S et al. Cost utility of ERCP-based modalities for the diagnosis of cholangiocarcinoma in primary sclerosing cholangitis. *Gastrointest Endosc* 2017; 85: 773–781 e710 doi:10.1016/j.gie.2016.08.020
- [130] Gordon IO, Sherman JD, Leapman M et al. Life cycle greenhouse gas emissions of gastrointestinal biopsies in a surgical pathology laboratory. *Am J Clin Pathol* 2021; 156: 540–549 doi:10.1093/ajcp/aqab021
- [131] Wang KX, Ben QW, Jin ZD et al. Assessment of morbidity and mortality associated with EUS-guided FNA: a systematic review. *Gastrointest Endosc* 2011; 73: 283–290
- [132] Otsuka Y, Kamata K, Hyodo T et al. Utility of contrast-enhanced harmonic endoscopic ultrasonography for T-staging of patients with extrahepatic bile duct cancer. *Surg Endosc* 2022; 36: 3254–3260
- [133] Fritscher-Ravens A, Broering DC, Knoefel WT et al. EUS-guided fine-needle aspiration of suspected hilar cholangiocarcinoma in potentially operable patients with negative brush cytology. *Am J Gastroenterol* 2004; 99: 45–51
- [134] Raine T, Thomas JP, Brais R et al. Test performance and predictors of accuracy of endoscopic ultrasound-guided fine-needle aspiration for diagnosing biliary strictures or masses. *Endosc Int Open* 2020; 8: E1537–E1544 doi:10.1055/a-1231-4948

- [135] Levy MJ, Heimbach JK, Gores GJ. Endoscopic ultrasound staging of cholangiocarcinoma. *Curr Opin Gastroenterol* 2012; 28: 244–252 doi:10.1097/MOG.0b013e32835005bc
- [136] Mohamadnejad M, DeWitt JM, Sherman S et al. Role of EUS for pre-operative evaluation of cholangiocarcinoma: a large single-center experience. *Gastrointest Endosc* 2011; 73: 71–78 doi:10.1016/j.gie.2010.08.050
- [137] Orzan RI, Pojoga C, Agoston R et al. Endoscopic ultrasound in the diagnosis of extrahepatic cholangiocarcinoma: what do we know in 2023? *Diagnostics (Basel)* 2023; 13: 1023
- [138] Chiang A, Theriault M, Salim M et al. The incremental benefit of EUS for the identification of malignancy in indeterminate extrahepatic biliary strictures: A systematic review and meta-analysis. *Endosc Ultrasound* 2019; 8: 310–317 doi:10.4103/eus.eus_24_19
- [139] Fujii-Lau LL, Thosani NC, Al-Haddad M et al. American Society for Gastrointestinal Endoscopy guideline on the role of endoscopy in the diagnosis of malignancy in biliary strictures of undetermined etiology: summary and recommendations. *Gastrointest Endosc* 2023; 98: 685–693 doi:10.1016/j.gie.2023.06.005
- [140] Gao RY, Wu BH, Shen XY et al. Overlooked risk for needle tract seeding following endoscopic ultrasound-guided minimally invasive tissue acquisition. *World J Gastroenterol* 2020; 26: 6182–6194 doi:10.3748/wjg.v26.i40.6182
- [141] Jaskolka JD, Asch MR, Kachura JR et al. Needle tract seeding after radiofrequency ablation of hepatic tumors. *J Vasc Interv Radiol* 2005; 16: 485–491 doi:10.1097/01.RVI.0000151141.09597.5F
- [142] Kitano M, Yoshida M, Ashida R et al. Needle tract seeding after endoscopic ultrasound-guided tissue acquisition of pancreatic tumors: A nationwide survey in Japan. *Dig Endosc* 2022 doi:10.1111/den.14346
- [143] Micames C, Jowell PS, White R et al. Lower frequency of peritoneal carcinomatosis in patients with pancreatic cancer diagnosed by EUS-guided FNA vs. percutaneous FNA. *Gastrointest Endosc* 2003; 58: 690–695
- [144] Ikezawa K, Uehara H, Sakai A et al. Risk of peritoneal carcinomatosis by endoscopic ultrasound-guided fine needle aspiration for pancreatic cancer. *J Gastroenterol* 2013; 48: 966–972 doi:10.1007/s00535-012-0693-x
- [145] Kim SH, Woo YS, Lee KH et al. Preoperative EUS-guided FNA: effects on peritoneal recurrence and survival in patients with pancreatic cancer. *Gastrointest Endosc* 2018; 88: 926–934
- [146] Facciorusso A, Crino SF, Gkolfakis P et al. Needle tract seeding after endoscopic ultrasound tissue acquisition of pancreatic lesions: a systematic review and meta-analysis. *Diagnostics (Basel)* 2022; 12: 2113 doi:10.3390/diagnostics12092113
- [147] El Chafic AH, Dewitt J, Leblanc JK et al. Impact of preoperative endoscopic ultrasound-guided fine needle aspiration on postoperative recurrence and survival in cholangiocarcinoma patients. *Endoscopy* 2013; 45: 883–889 doi:10.1055/s-0033-1344760
- [148] Heimbach JK, Sanchez W, Rosen CB et al. Trans-peritoneal fine needle aspiration biopsy of hilar cholangiocarcinoma is associated with disease dissemination. *HPB (Oxford)* 2011; 13: 356–360
- [149] Kahaleh M, Gaidhane M, Shahid HM et al. Digital single-operator cholangioscopy interobserver study using a new classification: the Mendoza Classification (with video). *Gastrointest Endosc* 2022; 95: 319–326
- [150] Behary J, Keegan M, Craig PI. The interobserver agreement of optical features used to differentiate benign from neoplastic biliary lesions assessed at balloon-assisted cholangioscopy. *J Gastroenterol Hepatol* 2019; 34: 595–602 doi:10.1111/jgh.14556
- [151] Zhang X, Tang D, Zhou JD et al. A real-time interpretable artificial intelligence model for the cholangioscopic diagnosis of malignant biliary stricture (with videos). *Gastrointest Endosc* 2023; 98: 199–210 e110
- [152] Robles-Medrand C, Baquerizo-Burgos J, Alcivar-Vasquez J et al. Artificial intelligence for diagnosing neoplasia on digital cholangioscopy: development and multicenter validation of a convolutional neural network model. *Endoscopy* 2023; 55: 719–727 doi:10.1055/a-2034-3803
- [153] Chen L, Lu Y, Wu JC et al. Diagnostic utility of endoscopic retrograde cholangiography/intraductal ultrasound (ERC/IDUS) in distinguishing malignant from benign bile duct obstruction. *Dig Dis Sci* 2016; 61: 610–617
- [154] Stavropoulos S, Larghi A, Verna E et al. Intraductal ultrasound for the evaluation of patients with biliary strictures and no abdominal mass on computed tomography. *Endoscopy* 2005; 37: 715–721
- [155] Slivka A, Gan I, Jamidar P et al. Validation of the diagnostic accuracy of probe-based confocal laser endomicroscopy for the characterization of indeterminate biliary strictures: results of a prospective multicenter international study. *Gastrointest Endosc* 2015; 81: 282–290 doi:10.1016/j.gie.2014.10.009
- [156] Gerges C, Beyna T, Tang RSY et al. Digital single-operator peroral cholangioscopy-guided biopsy sampling versus ERCP-guided brushing for indeterminate biliary strictures: a prospective, randomized, multicenter trial (with video). *Gastrointest Endosc* 2020; 91: 1105–1113
- [157] Draganov PV, Chauhan S, Wagh MS et al. Diagnostic accuracy of conventional and cholangioscopy-guided sampling of indeterminate biliary lesions at the time of ERCP: a prospective, long-term follow-up study. *Gastrointest Endosc* 2012; 75: 347–353 doi:10.1016/j.gie.2011.09.020
- [158] Sekine K, Yasuda I, Doi S et al. Peroral cholangioscopy-guided targeted biopsy versus conventional endoscopic transpapillary forceps biopsy for biliary stricture with suspected bile duct cancer. *J Clin Med* 2022; 11: 289
- [159] Sethi A, Chen YK, Austin GL et al. ERCP with cholangiopancreatography may be associated with higher rates of complications than ERCP alone: a single-center experience. *Gastrointest Endosc* 2011; 73: 251–256
- [160] Thosani N, Zubarik RS, Kochar R et al. Prospective evaluation of bacteremia rates and infectious complications among patients undergoing single-operator choledochoscopy during ERCP. *Endoscopy* 2016; 48: 424–431
- [161] Othman MO, Guerrero R, Elhanafi S et al. A prospective study of the risk of bacteremia in directed cholangioscopic examination of the common bile duct. *Gastrointest Endosc* 2016; 83: 151–157 doi:10.1016/j.gie.2015.05.018
- [162] Gustafsson A, Enochsson L, Tingstedt B et al. Antibiotic prophylaxis and post-procedure infectious complications in endoscopic retrograde cholangiopancreatography with peroral cholangioscopy. *Endosc Int Open* 2023; 11: E1177–E1183
- [163] Brand M, Bizos D, O'Farrell P. Antibiotic prophylaxis for patients undergoing elective endoscopic retrograde cholangiopancreatography. *Cochrane Database Syst Rev* 2010; 2010: CD007345 doi:10.1002/14651858.CD007345.pub2
- [164] Deprez PH, Garces Duran R, Moreels T et al. The economic impact of using single-operator cholangioscopy for the treatment of difficult bile duct stones and diagnosis of indeterminate bile duct strictures. *Endoscopy* 2018; 50: 109–118
- [165] Repici A, Khalaf K, Troncone E et al. International Delphi Consensus Study on disposable single-use endoscopy: A path to clinical adoption. *Dig Liver Dis* 2024; 56: 322–329 doi:10.1016/j.dld.2023.07.026