

Oncological Resectability Criteria for Hepatocellular Carcinoma in the Era of Novel Systemic Therapies: The Japan Liver Cancer Association and Japanese Society of Hepato-Biliary-Pancreatic Surgery Expert Consensus Statement 2023

Keiichi Akahoshi^a Junichi Shindoh^b Minoru Tanabe^a Shunichi Ariizumi^c
Susumu Eguchi^d Yukiyasu Okamura^e Masaki Kaibori^f Shoji Kubo^g
Mitsuo Shimada^h Akinobu Taketomiⁱ Nobuyuki Takemura^j
Hiroaki Nagano^k Masafumi Nakamura^l Kiyoshi Hasegawa^m
Etsuro Hatanoⁿ Tomoharu Yoshizumi^o Itaru Endo^p Norihiro Kokudo^j

^aDepartment of Hepatobiliary and Pancreatic Surgery, Tokyo Medical and Dental University, Tokyo, Japan;

^bDepartment of Gastroenterological Surgery, Toranomon Hospital, Tokyo, Japan; ^cInstitute of Gastroenterology, Tokyo Women's Medical University, Tokyo, Japan; ^dDepartment of Surgery, Graduate School of Biomedical Sciences, Nagasaki University, Nagasaki, Japan; ^eDivision of Digestive Surgery, Department of Surgery, Nihon University School of Medicine, Tokyo, Japan; ^fDepartment of Surgery, Kansai Medical University, Osaka, Japan;

^gDepartment of Hepato-Biliary-Pancreatic Surgery, Osaka Metropolitan University Graduate School of Medicine, Osaka, Japan; ^hDepartment of Digestive and Transplant Surgery, Tokushima University Hospital, Tokushima, Japan; ⁱDepartment of Gastroenterological Surgery I, Hokkaido University Graduate School of Medicine, Hokkaido, Japan; ^jDepartment of Surgery, Hepato-Biliary Pancreatic Surgery Division, National Center for Global Health and Medicine, Tokyo, Japan; ^kDepartment of Gastroenterological, Breast and Endocrine Surgery, Yamaguchi University Graduate School of Medicine, Yamaguchi, Japan; ^lDepartment of Surgery and Oncology, Graduate School of Medical Sciences, Kyushu University, Fukuoka, Japan; ^mHepato-Biliary-Pancreatic Surgery Division, Graduate School of Medicine, The University of Tokyo, Tokyo, Japan; ⁿDepartment of Surgery, Graduate School of Medicine, Kyoto University, Kyoto, Japan; ^oDepartment of Surgery and Science, Graduate School of Medical Sciences, Kyushu University, Fukuoka, Japan; ^pDepartment of Gastroenterological Surgery, Yokohama City University, Kanagawa, Japan

Keywords

Hepatocellular carcinoma · Resectability · Oncological criteria · Consensus · Borderline resectable

Keiichi Akahoshi and Junichi Shindoh contributed equally to this work.

Abstract

Recent advances in systemic therapy for hepatocellular carcinoma (HCC) have led to debates about the feasibility of combination therapies, such as systemic therapy combined with surgery or transarterial chemoembolization, for patients with advanced HCC. However, a lack of consensus on the oncological resectability criteria has hindered discussions of “conversion therapy” and the optimal management in patients with HCC. To address this issue, the Japan Liver Cancer Association (JLCA) and the Japanese Society of Hepato-Biliary-Pancreatic Surgery (JSHBPS) established a working group and discussed the concept of borderline resectable HCC. Herein, we present a consensus statement from this expert panel on the resectability criteria for HCC from the oncological standpoint under the assumption of technically and liver-functionally resectable situations. The criteria for oncological resectability in HCC are classified into three grades: resectable, representing an oncological status for which surgery alone may be expected to offer clearly better survival outcomes as compared with other treatments; borderline resectable 1, representing an oncological status for which surgical intervention as a part of multidisciplinary treatment may be expected to offer survival benefit; and borderline resectable 2, representing an oncological status for which the efficacy of surgery is uncertain and the indication for surgery should be determined carefully under the standard multidisciplinary treatment. These criteria aim to provide a common language for discussing and analyzing the treatment strategies for advanced HCC. It is also expected that these criteria will be optimized, modified, and updated based on further advancements in systemic therapies and future validation studies.

© 2024 The Author(s).

Published by S. Karger AG, Basel

Introduction

Recent advances in systemic therapy for hepatocellular carcinoma (HCC) have provoked active discussions on combined modality therapies, such as surgery or transarterial chemoembolization (TACE) combined with systemic therapy, for patients with advanced HCC [1–7]. However, a lack of consensus on the oncological resectability criteria has precluded formulation of a clear definition of so-called “conversion therapy” for patients with HCC and hindered constructive discussions on the optimal management of patients with advanced HCC. In view of this clinical dilemma, the Japan Liver Cancer Association (JLCA) and the Japanese Society of Hepato-Biliary-Pancreatic Surgery (JSHBPS) established a working group

and discussed the concept of borderline resectable HCC (BR-HCC).

As the initial step prior to developing a consensus on the concept of BR-HCC, we conducted a questionnaire survey of expert Japanese hepatobiliary surgeons to ascertain their current views on the criteria for resectability in patients with HCC. The survey revealed both solid agreement and split opinions of the surgeons in regard to the surgical indications in marginal cases, including HCC patients with multiple lesions, vascular invasion, or extrahepatic spread (EHS) [8]. The concept of borderline resectable (BR) is well established in the field of pancreatic cancer because the degree of invasion in this cancer has been clearly identified as a predictor of the oncological suitability for surgery [9]. However, because optimal management of relapsed disease with various effective locoregional/systemic therapies has been shown to prolong the survival in patients with advanced HCC with a shorter recurrence-free survival after surgery [10, 11], technical resectability and oncological resectability do not always run in parallel in cases of advanced HCC. Given that one of the important roles of preoperative systemic therapy is to stratify patients according to their suitability for surgery, we considered it an urgent need to build a consensus on the oncological resectability criteria to guide clinical management in patients with advanced HCC in the current era of effective systemic therapies.

Toward this end, an expert panel was established in early 2023 to develop a consensus statement on the concept of BR-HCC, and multiple sessions of active discussions were held. Herein, we present the JLCA and JSHBPS Expert Consensus Statement 2023 on the oncological resectability criteria for HCC.

Methods

Expert Panel

The expert panel consisted of 17 expert hepatobiliary surgeons nominated from among members of the original working group for BR-HCC, committee members of General Rules for the Clinical and Pathological Study of Primary Liver Cancer, and committee members of the clinical guidelines of the Japanese Society of Hepatology. To ensure fairness and maintain anonymity, KA, who was in charge of the questionnaire survey of the Japanese expert surgeons on the resectability of HCC, acted as a coordinator for aggregating and analyzing the committee members' anonymous votes.

Discussion and Voting

The results of the questionnaire survey [8] of the expert Japanese hepatobiliary surgeons were initially presented to the panel, and key issues were identified through free discussions.

Table 1. Clinical questions and consensus statements

Clinical question	Consensus statement
CQ1 What should be the basic structure for presenting the oncological resectability criteria for HCC?	The oncological resectability criteria for HCC can be classified into three groups Group 1: oncological status for which surgery alone may be expected to offer clearly better survival outcomes as compared with other treatments Group 2: oncological status for which surgical intervention as a part of multidisciplinary treatment may be expected to offer survival benefit Group 3: oncological status for which the efficacy of surgery is uncertain and the indication for surgery should be carefully determined under the standard multidisciplinary treatment
CQ2 What is the optimal terminology for the three groups of oncological resectability criteria?	The oncological resectability criteria classified into three groups shall be named R, BR1, and BR2
CQ3 What is the resectability status of single HCC?	Single HCC is classified as R, regardless of the tumor size
CQ4 What is the upper limit for “R” in the case of multinodular HCC?	Multinodular HCC with up to 3 nodules, each measuring ≤ 3 cm in diameter is the upper limit of R
CQ5 What is the lower limit for “BR2” in the case of multinodular HCC?	Multinodular HCC with more than 5 nodules and/or any nodule measuring >5 cm in diameter is the lower limit for BR2
CQ6 How should we classify the resectability of portal vein invasion?	Vp0–1 is classified as R, Vp2–3 as BR1, and Vp4 as BR2
CQ7 How should we classify the resectability of hepatic vein invasion?	Vv0–1 is classified as R, Vv2 as BR1, and Vv3 as BR2
CQ8 How should we classify the resectability of bile duct invasion?	B0–1 is classified as R, B2–3 as BR1, and B4 as BR2
CQ9 What is the resectability of cases with extrahepatic spread (EHS)?	EHS is basically BR2, while localized EHS could be classified as BR1

Subsequently, clinical questions were formulated, and discussions were held based on the survey responses, existing data, and available evidence. Following this, a vote was held to formulate this consensus statement on the oncological resectability criteria for HCC (Table 1). Meetings of the expert panel were held three times between May 2023 and August 2023. The Expert Consensus Statement presented here defines the resectability criteria from an oncological standpoint under the assumption of technically and liver-functionally R situations.

Definition of Vascular Invasion

Degree of vascular invasion was described according to the Japanese staging system [12, 13]. Portal vein invasion was categorized into main trunk/contralateral branch (Vp4), first-order branch (Vp3), second-order branch (Vp2), and third-order branch or microscopic invasion (Vp1). Hepatic vein invasion was categorized as tumor thrombus in a peripheral hepatic vein, including microvascular invasion (Vv1), in a major hepatic vein (Vv2), or in the inferior vena cava (Vv3). Biliary invasion was categorized into common bile duct/contralateral branch (B4), first-order biliary tree (B3), second-order biliary tree (B2), and third-order biliary tree or microscopic invasion (B1).

Clinical Questions and Consensus Statement

Fundamental Definitions of the Oncological Resectability Criteria

CQ1: What Should Be the Basic Structure for Presenting the Oncological Resectability Criteria for HCC?

Recent advances in systemic therapy have brought changes in the treatment strategies adopted for HCC. The BCLC staging system has been updated and the clinical strategy for managing intermediate-stage HCC has been revised [14]. Oncologists have paid increasing attention to the effectiveness of combined modality therapies, such as systemic therapy combined with TACE [15–17]. Despite active discussions on conversion surgery in recent years, no revisions have been made in regard to expanding the indications for surgery.

Therefore, we first sought to clarify the actual views of Japanese hepatobiliary surgeons in relation to the management of patients with advanced HCC through a

questionnaire survey. The results suggested the openness of surgeons to potential expansion of the surgical indications in the current era of effective systemic therapies for patients with HCC [8]. Surgical indications for HCC vary considerably among the existing guidelines [18]. The EASL and ESMO guidelines essentially follow the BCLC guidelines, recommending liver resection in HCC patients with a solitary tumor of any size and those with multiple lesions within the Milan criteria, excluding cases with macrovascular invasion and/or EHS [19, 20]. In contrast, Japanese and Chinese guidelines offer relatively broad surgical indications, with no size limit for up to three lesions, and allow resection to be considered even for HCC patients showing macrovascular invasion [12, 21]. These differences in surgical indications between East and West could be partly attributed to the differences in the attitude of clinical management of HCC, especially with experiences of combination therapies for patients with advanced disease. Although there are no established neoadjuvant or adjuvant therapies for HCC, clinical trials, such as the LENS-HCC trial, the RACB trial, and the Cabo/Nivo trial, are currently investigating the effectiveness of neoadjuvant therapy for patients with HCC [22–24]. The positive results of the interim analysis of the IMbrave050 trial of adjuvant therapy for HCC imply that neoadjuvant and adjuvant therapies could become clinically applicable for patients with HCC in the near future [25].

A clear definition of an oncological status in which surgery alone would be expected to be associated with a poor prognosis, but surgery as a part of multidisciplinary treatment could yield an improved prognosis is an extremely important concept. Furthermore, among these, it is also important to distinguish between an oncological status in which the addition of surgery can be effective and that in which the significance of adding surgery needs to be judged very carefully; in the latter, systemic therapy should be placed at the center of treatment. Based on the above, we propose that it would be appropriate to classify the oncological resectability criteria for HCC into the following three groups.

Consensus Statement 1

The oncological resectability criteria for HCC can be classified into three groups:

- Group 1: oncological status for which surgery alone may be expected to offer clearly better survival outcomes as compared with other treatments.
- Group 2: oncological status for which surgical intervention as a part of multidisciplinary treatment may be expected to offer survival benefit.

- Group 3: oncological status for which the efficacy of surgery is uncertain and the indication for surgery should be carefully determined under the standard multidisciplinary treatment (voting results: agree 17 [100%]; disagree 0 [0%]).

CQ2: What Is the Optimal Terminology for the Three Groups of Oncological Resectability Criteria?

In the field of pancreatic cancer, resectability is classified into three grades: R, BR, and unresectable (UR) [9, 26]. For the case of colorectal liver metastases, various names are currently used to address the potential of cure with surgery, including “resectable,” “not optimally resectable,” “unresectable,” “never likely to be resectable,” “borderline resectable,” and “initially unresectable” [27–30].

In the questionnaire survey of the expert Japanese surgeons, although the questions were asked under the assumption of the technical feasibility of resection, the use of the term “UR” could have potentially evoked thoughts of the technical impossibility of resection, which could have potentially hindered the arrival at a consensus [8]. During the expert panel discussion, there were expectations that the definition of oncological resectability would expand the application of systemic therapies and other treatments for advanced HCC. On the other hand, concerns were also raised that the term “UR” might close the option of surgical treatment for some patients, leaving them at a clinical disadvantage. Unlike in patients with pancreatic cancer, determining the resectability in HCC patients presents different complexities. For instance, while multiple tumors are not typically found in pancreatic cancer, HCC often manifests as multiple intrahepatic nodules. Moreover, while contact with the major vessels in pancreatic cancer can easily lead to the determination of technical unresectability, which is not the case in HCC. Furthermore, the underlying liver function must be taken into consideration in the case of liver surgery. Yoh et al. [31] have addressed these complexities and proposed a resectability flowchart based on the liver function and technical aspects. Shindoh et al. [2] introduced the concept of “marginally R” to optimize the treatment strategies for advanced cases. The concept of these oncological criteria needs to be simple and less prone to misunderstandings to achieve broader acceptance, especially among hepatologists and radiologists.

The term “BR” is widely used, including in cases of pancreatic cancer, so that it might be appropriate and easy to accept the same term also for HCC. These oncological resectability criteria assume that resection is feasible based on technical and liver function criteria.

Fig. 1. Fundamental definition of the oncological resectability criteria. The criteria are classified into three groups. HCC, hepatocellular carcinoma.

R: Resectable
Oncological status for which surgery alone may be expected to offer clearly better survival outcomes as compared with other treatments
BR1: Borderline resectable 1
Oncological status for which surgical intervention as a part of multidisciplinary treatment may be expected to offer survival benefit
BR2: Borderline resectable 2 (initially unsuitable for resection)
Oncological status for which the efficacy of surgery is uncertain and the indication for surgery should be carefully determined under the standard multidisciplinary treatment

Still, the term “UR” tends to evoke thoughts of the impossibility of resection based on technical criteria, which could be misleading to some experts. While realistically, cases with such a tumor status may be unlikely to be candidates for surgical consideration, there is currently not sufficient evidence to assert that they will be permanently unsuitable for resection. Therefore, it was proposed that it might be appropriate to divide the BR status into two levels and name them borderline resectable 1 (BR1, group 2) and borderline resectable 2 (initially unsuitable for resection) (BR2, group 3).

Consensus Statement 2

The oncological resectability criteria classified into three groups shall be named R, BR1, and BR2 (voting results: agree 16 [94.1%]; disagree 1 [5.9%]). Through the above discussion, we defined the concepts and names of the three groups of oncological resectability criteria (Fig. 1).

Resectability Criteria in Relation to the Tumor Number and Size

CQ3: What Is the Resectability Status of Single HCC?

The questionnaire survey revealed that most respondents classified single HCC as “R,” regardless of the size of the tumor [8]. The Japanese guidelines, as well as the BCLC staging system and EASL/ESMO guidelines also consider all single HCCs as being an indication for resection [12, 14, 19, 20]. The AASLD guidelines classify solitary tumors measuring ≤ 5 cm in diameter as being suitable for resection [32].

A retrospective analysis of 403 cases from a single institution in Japan by Lim et al. [33] revealed no significant difference in the prognosis between patients with single HCC measuring 5–10 cm in diameter and those

with single HCC measuring more than 10 cm in diameter. A multivariable analysis in their study identified poor liver function and microvascular invasion, but not the tumor size, as being indicators of a poor prognosis. Kawaguchi et al. [34] analyzed the data from the National HCC database in Japan registered between 2000 and 2007, which covered 43,904 cases of HCC without portal vein invasion or distant metastasis; of the 43,904 cases, 15,313 underwent resection, 13,375 received TACE, and 15,216 underwent tumor ablation. The overall survival (OS) rates of the patients treated by each of these modalities were stratified in accordance with the tumor number and diameter of the largest tumor (maximum tumor diameter). These data could be assumed to reflect the pure effect of surgery in an era without effective systemic therapies. In single HCC, the 3-year and 5-year OS rates were 71.0% and 54.8%, respectively, in those with a tumor diameter of 5 cm, and 69.4% and 52.6%, respectively, in those with a tumor diameter of 10 cm. These results suggest that single HCCs show a favorable prognosis, even if the tumors are large in size (online suppl. Fig. 1; for all online suppl. material, see <https://doi.org/10.1159/000538627>). However, data on tumors larger than 10 cm are scarce, and the outcomes in patients with tumors larger than 10 cm were not calculated in this study. In reality, the opportunity for surgical resection in patients with solitary tumors measuring over 10 cm in diameter is rare. According to the 22nd National HCC Survey Report of Japan, among 7,646 cases of resection, only 7.5% of the tumors were larger than 10 cm in diameter [35]. While there was some discussion about whether BR1 should include single HCCs measuring ≥ 5 cm in diameter or ≥ 10 cm in diameter, the consensus favored categorizing single HCCs as “R,” regardless of the tumor size.

Consensus Statement 3

Single HCC is classified as R, regardless of the tumor size (voting results, agree 15 [88.2%]; disagree 2 [11.8%]).

CQ4: What Is the Upper Limit for “R” in the Case of Multinodular HCC?

CQ5: What Is the Lower Limit for “BR2” in the Case of Multinodular HCC?

In the case of multinodular HCC, the presence of up to 3 tumors with a maximum tumor size of 3 cm is classified as stage A disease according to the BCLC staging system. Patients with multinodular HCC classified as stage A disease are still considered as candidates for liver transplantation rather than as candidates for surgical resection; the EASL guidelines provide a similar recommendation [14, 19]. The AASLD guidelines classify HCC patients with up to 3 tumors with a maximum tumor diameter of 3 cm as candidates for surgical resection [32]. The Japanese and Chinese guidelines pose no tumor size restrictions for surgical resection in patients with up to 3 tumors [12, 21], and in the questionnaire survey, 76.4% of the surgeons favored 3 tumors as the upper limit for R. When the tumor number and maximum tumor diameter were taken into consideration together, the responses obtained as the upper limit for R could be grouped into three, as follows: (1) up to 3 nodules, with no size limit (27.9%); (2) up to 3 nodules measuring ≤ 5 cm in diameter each (21.4%); and (3) up to 3 nodules measuring ≤ 3 cm in diameter each (19.4%) [8]. According to an analysis of nationwide data in Japan, the 3-year/5-year OS rates were 67.6%/50.3% in patients with 3 tumors with a maximum tumor diameter of 3 cm, 56.5%/36.6% in patients with 3 tumors with a maximum tumor diameter of 5 cm, and 46.4%/25.9% in patients with 3 tumors with a maximum tumor diameter of 10 cm [34] (online suppl. Fig. 1). These data indicate that even in patients with the same number of tumors, larger maximum tumor diameters were associated with a poorer prognosis. Therefore, it is necessary to consider the number of tumors as well as the maximum tumor diameter to determine the oncological resectability of HCC. Kudo et al. [15] demonstrated that beyond up to 7 had a 3-year OS of 60% with LEN+TACE as compared to 40% with TACE alone. Considering the improvement in the prognosis of HCC patients treated by nonsurgical modalities due to the advances in systemic therapies in recent years, an upper limit of 3 tumors with a maximum tumor diameter of 3 cm was considered as the most appropriate upper limit for R, where surgery alone can be expected to yield a favorable prognosis.

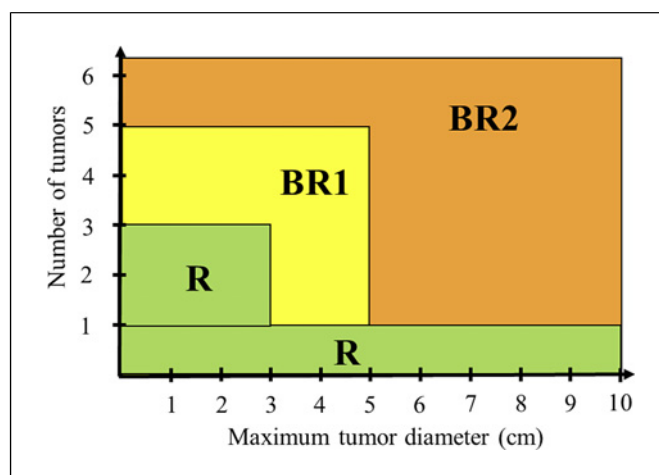


Fig. 2. Resectability criteria for HCC according to the number of tumor nodules and maximum tumor diameter. The vertical axis indicates number of tumors (n), and the horizontal axis indicates the maximum tumor diameter (cm). R, resectable; BR1, borderline resectable 1; BR2, borderline resectable 2.

In regard to CQ5, that is, the lower limit for “BR2,” the survey responses included 4 tumors, 5 tumors, and 5 tumors larger than 5 cm in diameter [8]. In a Japanese national data report, the 3-year/5-year OS rates after surgical resection were 50.0%/29.5% in HCC patients with 5 tumors with a maximum tumor diameter of 5 cm [34] (online suppl. Fig. 1); considering the 3-year OS of about 60% in the TACTICS-L trial reported by Kudo et al. [16], it is unlikely that resection can be considered for a tumor status worse than this. If we interpreted the 5-5-500 criteria used for transplantation [36] as the upper limit of the effectiveness of local therapies, presence of 5 tumors and a maximum tumor diameter of >5 cm would be a strong candidate as the lower limit for “BR2.”

Consensus Statement 4

Multinodular HCC with up to 3 nodules, each measuring ≤ 3 cm in diameter is the upper limit of R (voting results: agree 17 [100%]; disagree 0 [0%]).

Consensus Statement 5

Multinodular HCC with more than 5 nodules and/or any nodule measuring >5 cm in diameter is the lower limit for BR2 (voting results: agree 16 [94.1%]; disagree 1 [5.9%]). Through the above discussion, we defined the resectability criteria in relation to the tumor number and tumor diameter (Fig. 2).

Resectability Criteria in Relation to the Degree of Vascular Invasion

CQ6: How Should We Classify the Resectability of Portal Vein Invasion?

CQ7: How Should We Classify the Resectability of Hepatic Vein Invasion?

CQ8: How Should We Classify the Resectability of Bile Duct Invasion?

The BCLC guidelines consider vascular invasion as being outside the scope of surgical indications [14]. According to the Chinese guidelines, however, intrahepatic vascular invasion is not considered as a contraindication for resection, and the Japanese guidelines also do not exclude vascular invasion from the resectability criteria [12, 21]. Reviewing the extensive evidence in Japan that has provided broad surgical indications for vascular invasion, resectability of portal vein invasion (Vp) is classified according to the extent of invasion. The reported 5-year OS rates following resection in patients with venous invasion are as follows: Vp0, 70.1%; Vp1, 55.7%; Vp2, 41%; Vp3, 33%; and Vp4, 18.3% [35]. Even Vp1, when compared to Vp0, showed a worse prognosis. However, Vp1 is represented by microscopic features that cannot be detected preoperatively by imaging, so that its classification as BR1 may not be practical. The difference between Vp3 and Vp4 lies in the possibility of achieving R0 resection in the case of Vp3, while curative resection in cases of Vp4 presents difficulties. Therefore, it was proposed to classify Vp0–1 as R, Vp2–3 as BR1, and Vp4 as BR2.

In regard to hepatic vein invasion (Vv), Kokudo et al. analyzed Japanese national data registered between 2000 and 2007, which covered 540 resected cases and 481 non-resected cases and reported that the 3-year OS rates of cases with Vv1 and Vv2 were similar, being approximately 60%. Vv3 was associated with a 3-year OS of about 35% after resection, which was better than the 3-year OS of about 20% in patients who were not treated by resection [37]. However, even within cases with Vv3, there is considerable variation in the degree of tumor progression, which makes it necessary to exercise great caution in determining the surgical eligibility of patients with Vv3. Vv3 is associated with difficulties in curative resection, and the surgical approach can vary significantly depending on whether the tumor remains within the IVC or extends into the right atrium (RA). To a question in the survey about the validity of classifying Vv3 into Vv3-IVC and Vv3-RA in the future, 77% of the expert surgeons expressed agreement [8]. Furthermore, because dis-

tinguishing between Vv0 and Vv1 by preoperative imaging is challenging, it was suggested the Vv0–1 be classified as R, Vv2 as BR1, and Vv3 as BR2.

The question on resectability from the point of view of the degree of bile duct invasion (B) elicited the most divided opinions from the survey respondents [8]. It was agreed that B is rare, and even experts may have limited clinical experience. According to Japanese national data, among the cases treated by resection, 4.7% had Vp2 or higher, 2.1% had Vv2 or higher, and 1.4% had B2 or higher [35]. In one study, Yang et al. analyzed 270 cases from a single institution and reported that there was no significant difference in the post-resection prognosis between B0 and B1 cases, but that B2 or higher cases showed a significantly worse prognosis than the B0 and B1 cases. Study data stratifying B2–4 cases were not available in the literature [38]. While there was a consideration not to include B in the current oncological resectability criteria, the suggestion to classify B in line with the Vp and Vv classifications, and classify B0–1 as R, B2–3 as BR1, and B4 as BR2 also received support.

Consensus Statement 6

Vp0–1 is classified as R, Vp2–3 as BR1, and Vp4 as BR2 (voting results: agree 15 [88.2%]; disagree 2 [11.8%]).

Consensus Statement 7

Vv0–1 is classified as R, Vv2 as BR1, and Vv3 as BR2 (voting results: agree 17 [100%]; disagree 0 [0%]).

Consensus Statement 8

B0–1 is classified as R, B2–3 as BR1, and B4 as BR2 (voting results: agree 16 [94.1%]; disagree 1 [5.9%]).

Resectability Criteria in Relation to EHS

CQ9: What Is the Resectability of Cases with EHS?

Every published guideline classifies EHS as a contraindication for surgical resection. However, in clinical practice, cases of EHS that are relatively indolent and can be considered as oligometastatic, such as limited dissemination or adrenal metastasis, are sometimes encountered. Hasegawa et al. reported a 5-year OS of 29.5% after surgical resection in HCC patients with lymph node metastasis, which is generally considered as being associated with a poor prognosis, based on the analysis of Japanese national data [39]. Tomimaru et al. [40] suggested that HCC patients with a solitary or metachronous lymph node metastasis might have a favorable prognosis. The questionnaire survey supported considering solitary nodal involvement in No. 3,

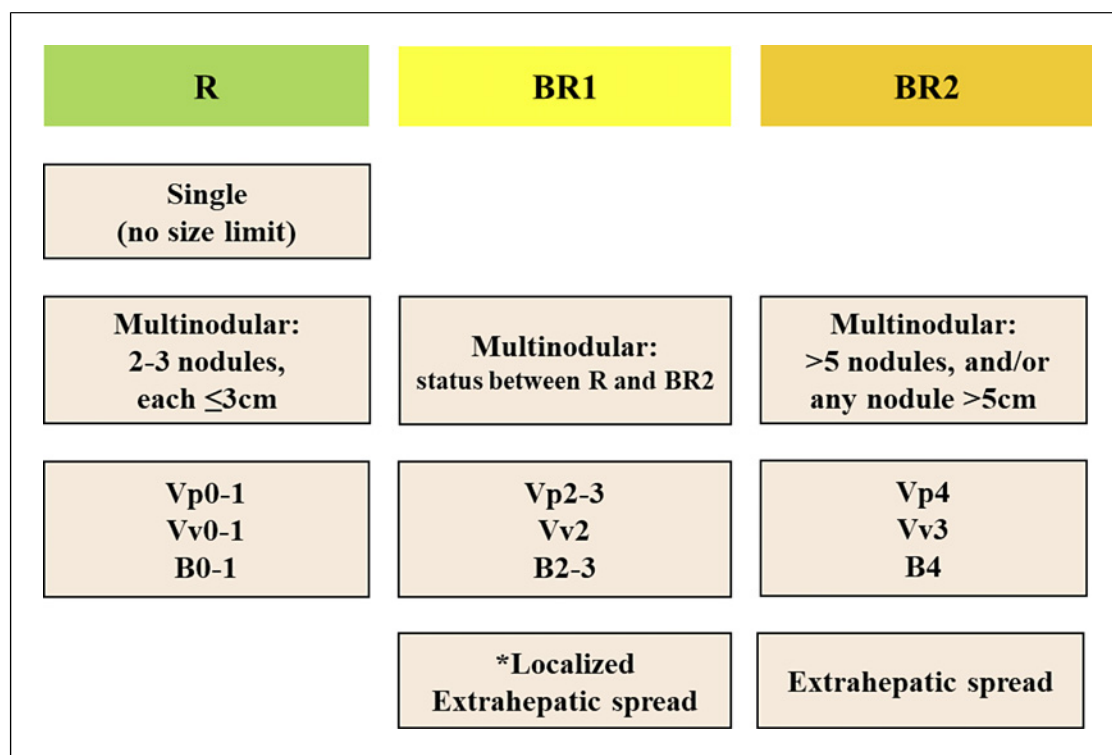


Fig. 3. Summary of the proposed oncological resectability criteria. Tumor conditions for R, BR1, and BR2 are illustrated. *Examples of localized EHS are as follows: solitary nodal involvement at no. 3, 8, or 12 lymph nodes, localized peritoneal dissemination, unilateral adrenal metastasis, or oligometastasis to the lung. R, resectable; BR1, borderline resectable 1; BR2, borderline resectable 2.

8, or 12 lymph node group as BR1 [8]. Evidence regarding the effectiveness of resection for peritoneal dissemination is extremely limited. Takemura et al. reported an overall 3-year OS of approximately 50% after resection in HCC patients with peritoneal dissemination, and a better prognosis was suggested under conditions in which the intrahepatic lesions were well controlled [41]. Therefore, considering localized dissemination as BR1 would seem reasonable. The prognosis after resection of HCC patients with adrenal metastases is generally poor [42, 43]. Teegen et al. reported cases from their experience with favorable outcomes after resection of unilateral adrenal metastases [44]. While adrenal metastases are generally classified as BR2, the survey as well as the expert panel discussions supported considering unilateral adrenal metastases as BR1, given the relatively minimal surgical invasiveness. The reported 5-year OS rates in HCC patients with lung metastasis vary widely, ranging from 27% to 66% [45–47]. Furthermore, it might be difficult for liver surgeons by themselves to determine the technical resectability of lung metas-

tases. Currently, there is limited evidence to define specific criteria based on the number or size of lung metastases. However, there was consensus support for considering cases with few lung metastases as BR1.

Consensus Statement 9

EHS is basically BR2, while localized EHS could be classified as BR1 (voting results: agree 15 [88.2%]; disagree 2 [11.8%]).

Summary of the Expert Consensus Statement

This Expert Consensus Statement on the oncological resectability criteria for HCC was compiled on the basis of the results of the questionnaire survey of expert Japanese surgeons and the evaluation of all the available evidence to date by an expert panel of liver surgeons (Fig. 3 and online suppl. Fig. 2). These criteria were developed to maximize the oncological benefits of surgery, under the premise that surgical resection is feasible based on the technical and liver function criteria. The oncological resectability criteria were

classified into the following three groups: R (resectable), BR1 (borderline resectable 1), and BR2 (borderline resectable 2). For each tumor factor, single HCC was classified as R without size restrictions. Multinodular HCC with ≤ 3 nodules with a maximum tumor diameter of ≤ 3 cm was also classified as R. Multinodular HCC with more than 5 nodules and/or any nodule > 5 cm in diameter was classified as BR2, and tumor conditions falling in between were classified as BR1. Vascular/bile duct invasion was categorized as follows: No macrovascular/bile duct invasion detected on imaging (Vp0–1 or Vv0–1/B0–1) was classified as R, macrovascular/bile duct invasion categorized as Vp2–3 or Vv2/B2–3 was classified as BR1, and major vascular/bile duct invasion (Vp4 or Vv3/B4) was classified as BR2. Furthermore, EHS was generally classified as BR2. Still, localized EHS (e.g., solitary nodal involvement at no. 3, 8, or 12 lymph nodes, localized peritoneal dissemination [i.e., P1], unilateral adrenal metastasis, or oligometastasis to the lung) could be classified as BR1.

These oncological resectability criteria are expected to serve as a common language for discussions and analyses related to multidisciplinary treatments for advanced HCC, contributing to future evidence construction. Additionally, these criteria are expected to be optimized, modified, and updated based on further advancements in systemic therapy and future validation studies.

Acknowledgments

We sincerely thank all the expert hepatobiliary and pancreatic surgeons who cooperated with the Japanese survey, which became the basis of this Consensus Statement. Also, I want to thank the

members of Tokyo Medical and Dental University, including Dr. Watanabe, Mr. Takamizawa, Dr. Asano, Dr. Ishikawa, Dr. Ueda, Dr. Ono, Dr. Kudo, Dr. Tanaka, Ms. Tasaki, Ms. Imaizumi, and Ms. Mizuno. Moreover, we would like to express our special gratitude to Dr. Yoshikuni Kawaguchi for giving us his kind permission to cite his article as one of the important sources of evidence for this Consensus Statement as shown in online supplementary Figure 1.

Conflict of Interest Statement

The authors have no conflict of interest to declare in relation to submission of this article.

Funding Sources

This work was supported by JSPS KAKENHI Grant Number 19K2390 and Program for Basic and Clinical Research on Hepatitis (JP23fk0210136) from Japan Agency for Medical Research and Development (AMED).

Author Contributions

N.K. and M.T. chaired and co-chaired the expert panel and designed the main concept of this project. J.S., M.T., S.A., S.E., I.E., Y.O., M.K., S.K., M.S., A.T., N.T., H.N., M.N., K.H., E.H., T.Y., and N.K. served as members of the expert panel, selecting the clinical questions, discussing the available evidence, and voting. K.A. acted as a coordinator for aggregating and analyzing the anonymous votes of the committee members. K.A. and J.S. drafted this manuscript, and all the authors discussed, revised, and approved this version of the manuscript for submission.

References

- Shindoh J, Kawamura Y, Kobayashi M, Akuta N, Okubo S, Matsumura M, et al. Prognostic advantages of individual additional interventions after lenvatinib therapy in patients with advanced hepatocellular carcinoma. *J Gastrointest Surg.* 2022;26(8):1637–46. <https://doi.org/10.1007/s11605-022-05388-9>.
- Shindoh J, Kawamura Y, Kobayashi Y, Kobayashi M, Akuta N, Okubo S, et al. Prognostic impact of surgical intervention after lenvatinib treatment for advanced hepatocellular carcinoma. *Ann Surg Oncol.* 2021;28(12):7663–72. <https://doi.org/10.1245/s10434-021-09974-0>.
- Itoh S, Toshida K, Morita K, Kurihara T, Nagao Y, Tomino T, et al. Clinical effectiveness of surgical treatment after lenvatinib administration for hepatocellular carcinoma. *Int J Clin Oncol.* 2022;27(11):1725–32. <https://doi.org/10.1007/s10147-022-02229-2>.
- Zhu XD, Huang C, Shen YH, Ji Y, Ge NL, Qu XD, et al. Downstaging and resection of initially unresectable hepatocellular carcinoma with tyrosine kinase inhibitor and anti-PD-1 antibody combinations. *Liver Cancer.* 2021;10(4):320–9. <https://doi.org/10.1159/000514313>.
- Peng Z, Fan W, Zhu B, Wang G, Sun J, Xiao C, et al. Lenvatinib combined with transarterial chemoembolization as first-line treatment for advanced hepatocellular carcinoma: a phase III, randomized clinical trial (LAUNCH). *J Clin Oncol.* 2023;41(1):117–27. <https://doi.org/10.1200/JCO.22.00392>.
- Kawamura Y, Kobayashi M, Shindoh J, Kobayashi Y, Okubo S, Tominaga L, et al. Lenvatinib-transarterial chemoembolization sequential therapy as an effective treatment at progression during lenvatinib therapy for advanced hepatocellular carcinoma. *Liver Cancer.* 2020;9(6):756–70. <https://doi.org/10.1159/000510299>.
- Kudo M. Atezolizumab plus bevacizumab followed by curative conversion (ABC conversion) in patients with unresectable, TACE-unsuitable intermediate-stage hepatocellular carcinoma. *Liver Cancer.* 2022;11(5):399–406. <https://doi.org/10.1159/000526163>.
- Akahoshi K, Shindoh J, Tanabe M, Watanabe S, Takamizawa H, Eguchi S, et al. Questionnaire survey of Japanese board-certified expert hepatobiliary and pancreatic surgeons and instructors on the surgical indications for hepatocellular carcinoma. *J Hepatobiliary Pancreat Sci.* 2024;31(3):143–51. <https://doi.org/10.1002/jhbp.1408>.

- 9 Isaji S, Mizuno S, Windsor JA, Bassi C, Fernandez-Del Castillo C, Hackert T, et al. International consensus of definition and criteria of borderline resectable pancreatic ductal adenocarcinoma 2017. *Pancreatol.* 2018;18(1):2–11. <https://doi.org/10.1016/j.pan.2017.11.011>.
- 10 Shindoh J, Kawamura Y, Kobayashi Y, Akuta N, Kobayashi M, Suzuki Y, et al. Time-to-Interventional Failure as a New Surrogate Measure for Survival Outcomes after Resection of Hepatocellular Carcinoma. *J Gastrointest Surg.* 2020;24(1):50–7. <https://doi.org/10.1007/s11605-019-04277-y>.
- 11 Shindoh J, Matsumura M, Kobayashi M, Akabane M, Okubo S, Hashimoto M. Disease-Free Interval and Behavior of Recurrent Hepatocellular Carcinoma. *Ann Surg Oncol.* 2023;30(6):3402–10. <https://doi.org/10.1245/s10434-023-13228-6>.
- 12 Hasegawa K, Takemura N, Yamashita T, Watanabe T, Kaibori M, Kubo S, et al. Clinical practice guidelines for hepatocellular carcinoma: the Japan society of hepatology 2021 version (5th JSH-HCC guidelines). *Hepatol Res.* 2023;53(5):383–90. <https://doi.org/10.1111/hepr.13892>.
- 13 Kudo M, Kitano M, Sakurai T, Nishida N. General Rules for the clinical and pathological study of primary liver cancer, nationwide follow-up survey and clinical practice guidelines: the outstanding achievements of the liver cancer study group of Japan. *Dig Dis.* 2015;33(6):765–70. <https://doi.org/10.1159/000439101>.
- 14 Reig M, Forner A, Rimola J, Ferrer-Fabrega J, Burrel M, Garcia-Criado A, et al. BCLC strategy for prognosis prediction and treatment recommendation: the 2022 update. *J Hepatol.* 2022;76(3):681–93. <https://doi.org/10.1016/j.jhep.2021.11.018>.
- 15 Kudo M, Ueshima K, Chan S, Minami T, Chishina H, Aoki T, et al. Lenvatinib as an initial treatment in patients with intermediate-stage hepatocellular carcinoma beyond up-to-seven criteria and child-pugh A liver function: a proof-of-concept study. *Cancers.* 2019;11(8):1084. <https://doi.org/10.3390/cancers11081084>.
- 16 Kudo M, Ueshima K, Saeki I, Ishikawa T, Inaba Y, Morimoto N, et al. A phase 2, prospective, multicenter, single-arm trial of transarterial chemoembolization therapy in combination strategy with lenvatinib in patients with unresectable intermediate-stage hepatocellular carcinoma: TACTICS-L trial. *Liver Cancer.* 2024;13(1):99–112. doi: 10.1159/000531377.
- 17 Kudo M, Han KH, Ye SL, Zhou J, Huang YH, Lin SM, et al. A changing paradigm for the treatment of intermediate-stage hepatocellular carcinoma: asia-pacific primary liver cancer expert consensus statements. *Liver Cancer.* 2020;9(3):245–60. <https://doi.org/10.1159/000507370>.
- 18 Ban D, Ogura T, Akahoshi K, Tanabe M. Current topics in the surgical treatments for hepatocellular carcinoma. *Ann Gastroenterol Surg.* 2018;2(2):137–46. <https://doi.org/10.1002/ags3.12065>.
- 19 European Association for the Study of the Liver Electronic address easloffice@easloffice.eu European Association for the Study of the Liver. EASL clinical practice guidelines: management of hepatocellular carcinoma. *J Hepatol.* 2018;69(1):182–236. <https://doi.org/10.1016/j.jhep.2018.03.019>.
- 20 Vogel A, Cervantes A, Chau I, Daniele B, Llovet JM, Meyer T, et al. Hepatocellular carcinoma: ESMO Clinical Practice Guidelines for diagnosis, treatment and follow-up. *Ann Oncol.* 2018;29(Suppl 4):iv238–55. <https://doi.org/10.1093/annonc/mdy308>.
- 21 Zhou J, Sun H, Wang Z, Cong W, Zeng M, Zhou W, et al. Guidelines for the diagnosis and treatment of primary liver cancer (2022 edition). *Liver Cancer.* 2023;12(5):405–44. <https://doi.org/10.1159/000530495>.
- 22 Ichida A, Arita J, Hatano E, Eguchi S, Saiura A, Nagano H, et al. A multicenter phase 2 trial evaluating the efficacy and safety of preoperative lenvatinib therapy for patients with advanced hepatocellular carcinoma (LENS-HCC trial). *Liver Cancer.* 2023;1–12. doi: 10.1159/000535514.
- 23 Okuno M, Ishii T, Ichida A, Soyama A, Takemura N, Hirono S, et al. Protocol of the RACB study: a multicenter, single-arm, prospective study to evaluate the efficacy of resection of initially unresectable hepatocellular carcinoma with atezolizumab combined with bevacizumab. *BMC Cancer.* 2023;23(1):780. <https://doi.org/10.1186/s12885-023-11302-6>.
- 24 Ho WJ, Zhu Q, Durham J, Popovic A, Xavier S, Leatherman J, et al. Neoadjuvant cabozantinib and nivolumab converts locally advanced HCC into resectable disease with enhanced antitumor immunity. *Nat Cancer.* 2021;2(9):891–903. <https://doi.org/10.1038/s43018-021-00234-4>.
- 25 Chow P, Chen M, Cheng AL, Kaseb AO, Kudo M, Lee HC, et al. Abstract CT003: IMbrave050: phase 3 study of adjuvant atezolizumab + bevacizumab versus active surveillance in patients with Hepatocellular Carcinoma (HCC) at high risk of disease recurrence following resection or ablation. *Cancer Res.* 2023;83(8_Suppl):CT003. <https://doi.org/10.1158/1538-7445.am2023-ct003>.
- 26 Katz MH, Pisters PW, Evans DB, Sun CC, Lee JE, Fleming JB, et al. Borderline resectable pancreatic cancer: the importance of this emerging stage of disease. *J Am Coll Surg.* 2008;206(5):833–48. <https://doi.org/10.1016/j.jamcollsurg.2007.12.020>.
- 27 Kaczirek K. Asco 2016: update colorectal liver metastases. *Memo.* 2017;10(2):103–5. <https://doi.org/10.1007/s12254-016-0308-y>.
- 28 Van Cutsem E, Cervantes A, Adam R, Sobrero A, Van Krieken JH, Aderka D, et al. ESMO consensus guidelines for the management of patients with metastatic colorectal cancer. *Ann Oncol.* 2016;27(8):1386–422. <https://doi.org/10.1093/annonc/mdw235>.
- 29 Vauthey JN. Colorectal liver metastases: treat effectively up front and consider the borderline resectable. *J Clin Oncol.* 2007;25(29):4524–5. <https://doi.org/10.1200/JCO.2007.13.1136>.
- 30 Kitano Y, Hayashi H, Matsumoto T, Kinoshita S, Sato H, Shiraishi Y, et al. Borderline resectable for colorectal liver metastases: present status and future perspective. *World J Gastrointest Surg.* 2021;13(8):756–63. <https://doi.org/10.4240/wjgs.v13.i8.756>.
- 31 Yoh T, Ishii T, Nishio T, Koyama Y, Ogiso S, Fukumitsu K, et al. A conceptual classification of resectability for hepatocellular carcinoma. *World J Surg.* 2023;47(3):740–8. <https://doi.org/10.1007/s00268-022-06803-7>.
- 32 Singal AG, Llovet JM, Yarchoan M, Mehta N, Heimbach JK, Dawson LA, et al. AASLD Practice Guidance on prevention, diagnosis, and treatment of hepatocellular carcinoma. *Hepatology.* 2023;78(6):1922–65. <https://doi.org/10.1097/HEP.000000000000466>.
- 33 Lim C, Mise Y, Sakamoto Y, Yamamoto S, Shindoh J, Ishizawa T, et al. Above 5 cm, size does not matter anymore in patients with hepatocellular carcinoma. *World J Surg.* 2014;38(11):2910–8. <https://doi.org/10.1007/s00268-014-2704-y>.
- 34 Kawaguchi Y, Hasegawa K, Hagiwara Y, De Bellis M, Famularo S, Panettieri E, et al. Effect of diameter and number of hepatocellular carcinomas on survival after resection, transarterial chemoembolization, and ablation. *Am J Gastroenterol.* 2021;116(8):1698–708. <https://doi.org/10.14309/ajg.0000000000001256>.
- 35 Kudo M, Izumi N, Kokudo N, Sakamoto M, Shiina S, Takayama T, et al. Report of the 22nd nationwide follow-up survey of primary liver cancer in Japan (2012–2013). *Hepatol Res.* 2022;52(1):5–66. <https://doi.org/10.1111/hepr.13675>.
- 36 Shimamura T, Akamatsu N, Fujiyoshi M, Kawaguchi A, Morita S, Kawasaki S, et al. Expanded living-donor liver transplantation criteria for patients with hepatocellular carcinoma based on the Japanese nationwide survey: the 5-5-500 rule: a retrospective study. *Transpl Int.* 2019;32(4):356–68. <https://doi.org/10.1111/tri.13391>.
- 37 Kokudo T, Hasegawa K, Matsuyama Y, Takayama T, Izumi N, Kadota M, et al. Liver resection for hepatocellular carcinoma associated with hepatic vein invasion: a Japanese nationwide survey. *Hepatology.* 2017;66(2):510–7. <https://doi.org/10.1002/hep.29225>.
- 38 Yang X, Qiu Z, Ran R, Cui L, Luo X, Wu M, et al. Prognostic importance of bile duct invasion in surgical resection with curative intent for hepatocellular carcinoma using PSM analysis. *Oncol Lett.* 2018;16(3):3593–602. <https://doi.org/10.3892/ol.2018.9108>.

- 39 Hasegawa K, Makuuchi M, Kokudo N, Izumi N, Ichida T, Kudo M, et al. Impact of histologically confirmed lymph node metastases on patient survival after surgical resection for hepatocellular carcinoma: report of a Japanese nationwide survey. *Ann Surg.* 2014; 259(1):166–70. <https://doi.org/10.1097/SLA.0b013e31828d4960>.
- 40 Tomimaru Y, Wada H, Eguchi H, Tomokuni A, Hama N, Kawamoto K, et al. Clinical significance of surgical resection of metastatic lymph nodes from hepatocellular carcinoma. *Surg Today.* 2015;45(9):1112–20. <https://doi.org/10.1007/s00595-014-1028-8>.
- 41 Takemura N, Hasegawa K, Aoki T, Sakamoto Y, Sugawara Y, Makuuchi M, et al. Surgical resection of peritoneal or thoracoabdominal wall implants from hepatocellular carcinoma. *Br J Surg.* 2014;101(8):1017–22. <https://doi.org/10.1002/bjs.9489>.
- 42 Ha TY, Hwang S, Ahn CS, Kim KH, Lee YJ, Moon DB, et al. Resection of metachronous adrenal metastasis after liver resection and transplantation for hepatocellular carcinoma. *Dig Surg.* 2014;31(6):428–35. <https://doi.org/10.1159/000370078>.
- 43 Park JS, Yoon DS, Kim KS, Choi JS, Lee WJ, Chi HS, et al. What is the best treatment modality for adrenal metastasis from hepatocellular carcinoma? *J Surg Oncol.* 2007; 96(1):32–6. <https://doi.org/10.1002/jso.20773>.
- 44 Teegen EM, Mogl MT, Pratschke J, Rayes N. Adrenal metastasis of hepatocellular carcinoma in patients following liver resection or liver transplantation: experience from a tertiary referral center. *Int J Surg Oncol.* 2018; 2018:4195076. <https://doi.org/10.1155/2018/4195076>.
- 45 Kuo SW, Chang YL, Huang PM, Hsu HH, Chen JS, Lee JM, et al. Prognostic factors for pulmonary metastasectomy in hepatocellular carcinoma. *Ann Surg Oncol.* 2007;14(2):992–7. <https://doi.org/10.1245/s10434-006-9217-3>.
- 46 Han KN, Kim YT, Yoon JH, Suh KS, Song JY, Kang CH, et al. Role of surgical resection for pulmonary metastasis of hepatocellular carcinoma. *Lung Cancer.* 2010;70(3):295–300. <https://doi.org/10.1016/j.lungcan.2010.02.014>.
- 47 Takahashi Y, Ikeda N, Nakajima J, Sawabata N, Chida M, Horio H, et al. Prognostic analysis of surgical resection for pulmonary metastasis from hepatocellular carcinoma. *World J Surg.* 2016;40(9):2178–85. <https://doi.org/10.1007/s00268-016-3580-4>.