

Society of Radiologists in Ultrasound Consensus on Routine Pelvic US for Endometriosis

Scott W. Young, MD* • Priyanka Jha, MBBS* • Luciana Chamié, MD, PhD • Shuchi Rodgers, MD • Rosanne M. Kho, MD • Mindy M. Horrow, MD • Phyllis Glanc, MD • Myra Feldman, MD • Yvette Groszmann, MD • Zaraq Khan, MBBS • Steven L. Young, MD, PhD • Liina Poder, MD • Tatnai L. Burnett, MD • Eric M. Hu, MD • Susan Egan, RDMS • Wendaline VanBuren, MD

From the Department of Radiology, Mayo Clinic Arizona, 5777 E Mayo Blvd, Phoenix, AZ 85054 (S.W.Y.); Department of Radiology, Stanford University School of Medicine, Stanford, Calif (P.J.); Department of Radiology, Chamié Imagem da Mulher, São Paulo, Brazil (L.C.); Department of Radiology, Albert Einstein Medical Center, Philadelphia, Pa (S.R., M.M.H.); Department of Obstetrics and Gynecology, Banner Health System, Phoenix, Ariz (R.M.K.); Department of Medical Imaging, University of Toronto, Toronto, Canada (P.G.); Imaging Institute, Cleveland Clinic Foundation, Cleveland, Ohio (M.F.); Department of Obstetrics and Gynecology, Brigham and Women's Hospital, Boston, Mass (Y.G.); Department of Obstetrics and Gynecology (Z.K., T.L.B.) and Department of Radiology (W.V.B.), Mayo Clinic, Rochester, Minn; Department of Obstetrics and Gynecology, Duke University School of Medicine, Durham, NC (S.L.Y.); Department of Radiology and Biomedical Imaging, University of California, San Francisco, San Francisco, Calif (L.P.); Department of Radiology, Intermountain Healthcare, Salt Lake City, Utah (E.M.H.); and Department of Radiology, Rutgers Robert Wood Johnson Medical School, Piscataway, NJ (S.E.). Received August 24, 2023; revision requested October 31; revision received November 21; accepted December 22.

Address correspondence to S.W.Y. (email: Young.Scott@mayo.edu).

* S.W.Y. and P.J. contributed equally to this work.

Conflicts of interest are listed at the end of this article.

Radiology 2024; 311(1):e232191 • <https://doi.org/10.1148/radiol.232191> • Content codes: **OB** **US**

Endometriosis is a prevalent and potentially debilitating condition that mostly affects individuals of reproductive age, and often has a substantial diagnostic delay. US is usually the first-line imaging modality used when patients report chronic pelvic pain or have issues of infertility, both common symptoms of endometriosis. Other than the visualization of an endometrioma, sonologists frequently do not appreciate endometriosis on routine transvaginal US images. Given a substantial body of literature describing techniques to depict endometriosis at US, the Society of Radiologists in Ultrasound convened a multidisciplinary panel of experts to make recommendations aimed at improving the screening process for endometriosis. The panel was composed of experts in the imaging and management of endometriosis, including radiologists, sonographers, gynecologists, reproductive endocrinologists, and minimally invasive gynecologic surgeons. A comprehensive literature review combined with a modified Delphi technique achieved a consensus. This statement defines the targeted screening population, describes techniques for augmenting pelvic US, establishes direct and indirect observations for endometriosis at US, creates an observational grading and reporting system, and makes recommendations for additional imaging and patient management. The panel recommends transvaginal US of the posterior compartment, observation of the relative positioning of the uterus and ovaries, and the uterine sliding sign maneuver to improve the detection of endometriosis. These additional techniques can be performed in 5 minutes or less and could ultimately decrease the delay of an endometriosis diagnosis in at-risk patients.

© RSNA, 2024

Supplemental material is available for this article.

Endometriosis, defined as the presence of endometrium-like tissue outside the uterus, is a common condition estimated to affect 10% of those of reproductive age and occurs in 21% of female patients undergoing hysterectomy with chronic pelvic pain (1). It is also associated with infertility and subfertility, affecting 20%–50% of patients with these conditions (2). Deep endometriosis (DE), traditionally considered to extend more than 5 mm under the peritoneal surface but redefined in 2021 as extending to any depth beneath the peritoneal surface, is the most severe form of endometriosis (3).

Transvaginal sonography is used worldwide as a first-line modality for pelvic pain and infertility evaluation. It has also been advocated as a second-line modality for preoperative mapping of endometriomas and DE observations, after an initial diagnosis of DE has been established (4–7). Yet, in the United States, there is a delay longer than 7 years between the onset of symptoms and diagnosis of endometriosis (8,9). Although transvaginal US is commonly interpreted by sonologists (radiologists and gynecologists) in the United States, few centers use US as a screening modality for DE

(10). Existing scan protocol limitations and lack of awareness lead to suboptimal detection of DE on pelvic US images (11). Detailed and systematic approaches for diagnosing endometriosis published previously are not widely used in the United States (6,7,12), most notably the recommendations from the 2016 International Deep Endometriosis Analysis group (13). These protocols involve an expert sonologist who obtains numerous additional images that are outside of the current interdisciplinary guideline, the typical time allotted for pelvic imaging, and reimbursement models. Failure to diagnose DE at routine sonography likely contributes to diagnostic delay (14). Moreover, gynecologic surgical societies now recommend advanced endometriosis imaging before laparoscopic evaluation (15). This is particularly important because extensive dissection may be required to detect DE at laparoscopy. Preoperative imaging allows for appropriate patient counseling and surgical planning including the need for additional surgical expertise beyond that of a general laparoscopist (16).

DE manifests in the posterior compartment of 93% of affected patients, including the uterosacral ligaments

Abbreviations

DE = deep endometriosis, O-RADS = Ovarian-Adnexal Reporting and Data System, USL = uterosacral ligament

Summary

The Society of Radiologists in Ultrasound expert consensus provides recommendations for augmenting routine pelvic US examinations through additional maneuvers and imaging to improve diagnosis of deep endometriosis.

Essentials

- The Society of Radiologists in Ultrasound expert panel recommends performing augmented pelvic US in premenopausal or early postmenopausal individuals (<5 years since the cessation of menses) who are symptomatic for or have a history of endometriosis or infertility.
- Additional techniques to augment pelvic US examinations include transvaginal US of the posterior compartment, observation of the relative positioning of the uterus and ovaries, and the uterine sliding sign maneuver.
- Direct and indirect observations of deep endometriosis should be assessed during the examination and results should be reported using four categories: Incomplete (augmented pelvic US, or APU-0), normal (APU-1), equivocal (APU-2), and positive (APU-3) with associated management recommendations.

(USLs) (69%) and rectum and rectosigmoid junction (10%–20%) (17,18). These areas are easily accessible with transvaginal US, and focused imaging of these regions is likely to have the greatest impact on expediting the diagnosis. The current interdisciplinary imaging guideline does not specify sonographic techniques or scanning protocols targeted to diagnosing endometriosis (19). Many prospective cohort studies and meta-analyses have shown good sensitivity and excellent specificity for the diagnosis, depending on location (5,20–31).

Most of these studies have been performed in patient populations at high risk for DE, often by experienced physician sonologists. The sensitivity and specificity for the detection of DE in a symptomatic patient by sonographers and subsequently interpreted by sonologists are not well known. However, in one study of average-risk patients (high-risk, tertiary care patients underwent endometriosis protocol MRI [32] or physician-acquired US-based DE mapping after bowel preparation [6]), the introduction of uterine sliding sign and static imaging of the posterior compartment with a review of cervicouterine cine clips performed solely by nonphysician sonographers and interpreted remotely by radiologists increased the detection of posterior compartment DE by three-fold and yielded sensitivity and specificity of 68% and 98%, respectively (33).

The purpose of this consensus panel is to recommend methods that increase the diagnostic sensitivity for endometriosis at pelvic US by increasing awareness, improving interpretation, adding simple techniques that are high yield for DE, and improving protocols to triage patients. The recommendations are expected to add minimal time to the current recommended protocols. This statement defines the targeted screening population, describes techniques for augmenting pelvic US, establishes direct and indirect observations for endometriosis at US, creates an observational grading and

reporting system, and makes recommendations for additional imaging and patient management.

Materials and Methods

Note on Terminology

The Society of Radiologists in Ultrasound panel recognizes that there are individuals who may be affected by endometriosis who are transgender, who do not identify with the term *female*, who do not menstruate, or who have undergone hysterectomy. The terms *female* and *reproductive age* are used in this statement to maintain consistency with the existing literature and their use is not intended to exclude or marginalize any individual affected by this debilitating disease.

Expert Panel

In June 2022, the Society of Radiologists in Ultrasound convened a panel of 16 experts in imaging and management of endometriosis. The panel included gynecologic US experts from both radiology and gynecology; a community radiologist; a registered diagnostic medical sonographer; board members or practice guideline chairs from key stakeholder societies such as the Society for Reproductive Endocrinology and Infertility (2), the American Society for Reproductive Medicine (1), the Society of Gynecologic Surgeons (1), the American Association of Gynecologic Laparoscopists (1), the Society of Reproductive Surgeons (1), the American Institute of Ultrasound in Medicine (1), and the Society for Assisted Reproductive Technology (1); minimally invasive gynecologic surgeons with expertise in the resection of advanced-stage DE (3); and cochairs or members of Society of Abdominal Radiology disease-focused panel on endometriosis (8). All the solicited experts agreed to join the panel.

Literature Search

A literature review was conducted to obtain the following information regarding the use of pelvic US in detecting endometriosis: sensitivities and specificities for detection in various locations, technique descriptions, and examples of direct observations (ie, the presence of ectopic endometrial tissue) and indirect observations (ie, a fibrotic reaction induced by endometriosis). A librarian performed a comprehensive English-language search in PubMed for literature published from January 1994 to December 2022. The following search strategy was used: (((("deep infiltrating endometriosis") OR ("deep infiltrating") AND ("Endometriosis"[Mesh])) AND (English[Filter])) OR ("deep* infiltrat* endometriosis" AND (English[Filter]))) OR ("deep* endometriosis" AND (English[Filter])) AND (English[Filter])) AND (ultrasound AND (English[Filter])) ± Filters: Meta-Analysis, Systematic Review, English. The results yielded 637 general literature articles and 21 meta-analyses. Of the 637 articles, 205 were excluded because they were older than 10 years or were case reports. Two authors (S.W.Y. and R.M.K.) reviewed the abstracts of the remaining 432 articles and excluded an additional 289 publications and four meta-analyses because they did not directly study US of DE. Seventy-five articles described site-specific or multisite direct

observations. These articles were categorized into six groups based on endometriosis site (Table 1; structured literature flow diagram, Fig S1). Each of the site-specific groups was assigned to one panel member who reviewed the full article. Those panel members also reviewed the full articles reporting on multisite direct observations. Meta-analyses reporting the sensitivity and specificity of direct transvaginal US observations were identified (Table 2). The remaining studies included 14 learning curve articles, 16 mobility and indirect observations articles, and 55 other articles that were deemed relevant to US-based DE. One panel member reviewed these articles. All panel members reviewed the meta-analyses.

Table 1: Distribution of Studies Identified During Structured Literature Review Based on Sites of Deep Endometriosis and Endometrioma

Deep Endometriosis Site	No. of Publications Reviewed
Retrocervical area, uterosacral ligaments, or multiple sites	44
Rectosigmoid colon or rectovaginal septum	10
Uterus or adenomyosis	10
Anterior compartment	5
Endometrioma	3
Distant sites	3

Expert Consensus

Simultaneously with the structured literature review, panel members completed a survey to gather expert opinions to augment the literature review. Panelists answered 35 multiple-choice questions based on the following topics: general goals of the recommendations for pelvic US examinations, patient inclusion criteria for augmented pelvic US, imaging techniques for endometriosis, time constraints for image acquisition, and direct and indirect observations of endometriosis at US and

Table 2: Meta-Analysis–derived Sensitivities and Specificities for Deep Endometriosis Observations at Transvaginal US

Location	Sensitivity (%)	Specificity (%)	Reference No.
Deep endometriosis (all areas)	57–98	87–100	20–23
Bladder	55–72	99–100	20,24–26
Uterosacral ligaments	56–67	86–93	20,25,27,28
Vaginal	52–58	96–98	21,25
Rectosigmoid colon	80–91	94–97	5,20,27,29,30
Ovarian endometrioma	93	96	31

Table 3: Consensus Definitions of Pelvic US Types and Categorization of Imaging Signs Relevant to the Imaging-based Detection of Endometriosis

Terminology	Definition
Imaging procedures	
Routine pelvic US	Conventional examination for all conditions pertaining to the uterus, ovary, adnexa, and the overall pelvis. Indications include all conditions pertaining to the pelvic organs for which imaging is required for diagnosis. Minimum standard US views should be obtained as mandated by practice guidelines. Allotted time varies between 30 and 45 min among the panelists' institutions.
Augmented pelvic US	A routine pelvic US augmented by additional maneuvers when clinical suspicion of endometriosis exists. Indications include chronic pelvic pain, infertility, and clinically or radiographically suspected endometriosis. Simple additional maneuvers such as uterine sliding cine, longitudinal and transverse sweeps of the uterus and cervix that include the posterior compartment structures can be used to assess endometriosis. Expected additional time: 2–5 min.
Advanced endometriosis imaging	Second line imaging evaluation, performed to diagnose endometriosis, evaluate disease extent, and aid in surgical planning when clinically indicated. May be either US or MRI performed/assessed by an expert, based on institutional practice patterns and available technology and expertise. US should include expert mapping of DE following a prescribed pattern of search (eg, IDEA protocol [13]). MRI should include endometriosis-specific MRI with expert interpretation. Detailed discussion of expert examinations is beyond the scope of current consensus (4,6,13,32,69).
Imaging signs of endometriosis	
Direct US observation	US observations indicating presence of ectopic endometrium-like tissue outside the uterus with visualization of DE implants.
Indirect US observation	Signs at US suggestive of or secondary to endometriosis without direct visualization of DE implants, such as adhesions or fixed uterine retroflexion.

Note.—DE = deep endometriosis, IDEA = International Deep Endometriosis Analysis.

Table 4: Summary of Panel Consensus Recommendations for Augmented Pelvic US for Detection of Endometriosis

Recommendation Category	Recommendation Summary
Screening population	Perform augmented pelvic US only in premenopausal or early postmenopausal individuals (<5 years since the cessation of menses). Patients should have chronic pelvic pain symptoms, infertility, or clinically or radiographically suspected endometriosis. The panel does not recommend performing augmented maneuvers routinely for all pelvic US.
Augmented pelvic US technique	The panel unanimously agreed that an augmented pelvic US would have the greatest acceptance and impact in general US-based screening for DE. Additional imaging to enhance the detection of DE during augmented pelvic US focuses on the transvaginal evaluation of the posterior compartment, the relative positioning of the uterus and ovaries, and the uterine sliding sign. Transvaginal US is essential for screening detection of DE and transabdominal examination alone is insufficient. When transvaginal imaging is not feasible or technically inadequate, use expert MRI if there is high clinical suspicion for endometriosis. The panel does not recommend bowel preparation for augmented pelvic US.
Augmented pelvic US observations	Assess direct and indirect signs during augmented pelvic US.
Augmented pelvic US reporting and clinical recommendations	Report augmented pelvic US using four categories: incomplete (APU-0), normal (APU-1), equivocal (APU-2), and positive (APU-3). Any single direct imaging observation (category A) of endometriosis should lead to endometriosis diagnosis, recommendation for advanced endometriosis imaging, and referral to a reproductive endocrinologist and/or gynecologic surgeon familiar with DE, as appropriate. In the absence of category A observations, findings are suggestive of endometriosis when two or more indirect observations (category B) or one category B and one endometriosis-associated observation (category C) are noted; referral to gynecology for further evaluation and possible advanced endometriosis imaging is recommended. When only category C observations are present, a gynecology referral is appropriate. Given the nonspecific nature of these findings, advanced endometriosis imaging is not recommended but may be obtained if there is high clinical suspicion of endometriosis. Advanced endometriosis imaging consists of either expert US mapping of endometriosis following a prescribed pattern of search and/or endometriosis-specific MRI with expert interpretation (4,6,13,32,69).

Note.—APU = augmented pelvic US, DE = deep endometriosis.

when to recommend advanced endometriosis imaging or gynecologic referral. The panel achieved consensus utilizing the modified Delphi method, which included up to seven rating rounds of multiple-choice questions with two to 10 options each and free text answers (Appendix S1). Panel-wide discussion of the survey created agreement regarding terminology and narrowed the options until consensus was achieved. Virtual discussions were recorded for those not able to attend in real time, with an opportunity to comment on the final consensus results. After consensus was reached regarding the relevant observational categories, the imagers (ie, radiologists and gynecologists) created diagnostic categories to stratify risk and need for follow-up based on expert opinion. Subsequently, the clinicians (gynecologists and gynecologic surgeons) achieved consensus regarding the appropriate management recommendations for the diagnostic categories.

Consensus Summary and Recommendations

For the purposes of the consensus, definitions for routine pelvic US, augmented pelvic US, advanced endometriosis imaging, and direct and indirect signs of DE were developed (Table 3) (34–39).

The consensus panel unanimously agreed that routine pelvic US techniques have not been optimized for the depiction of endometriosis and can thus exacerbate diagnostic delay in symptomatic patients. The panel agreed to raise awareness of the signs of endometriosis on all pelvic US images and list additional sonographic maneuvers that can augment the examination to depict DE. Table 4 lists a summary of consensus panel recommendations. Management recommendations should be guidance rather than requirements and are based on patients with average risk (nontertiary care) and typical symptoms.

Identifying the Screening Population

Recommendation: Perform augmented pelvic US only in premenopausal or early postmenopausal patients (<5 years since the cessation of menses). Patients should be symptomatic or have a history of infertility based on imaging indication or patient-provided history (40).

The panel identified patient history and symptoms that met the criteria for screening for DE at augmented pelvic US in premenopausal or early postmenopausal patients based on literature search and expert consensus (Table 5) (40–42). Although the predictive value of the listed endometriosis symptoms is low (41), current

Table 5: Patient Symptoms or History That Meet Criteria for Augmented Pelvic US

Parameter

Symptom

Cyclical or noncyclical chronic pelvic pain

Cyclical abdominal and/or pelvic pain

Deep dyspareunia

Dyschezia

Dysmenorrhea

Abdominal wall mass with cyclic pain

Unexplained dysuria

History

Endometriosis

Infertility

Suspected endometriosis on clinical examination

Radiologically suspected endometriosis

Note.—Criteria based on references 40–42.

guidelines do not recommend surgical or medical treatment for asymptomatic endometriosis (15). In clinical practice, patients meeting the criteria for screening can be identified by the clinical providers at the time of ordering the examination, by the sonographer during patient intake and scanning, and, ultimately, by the sonologist, who will be interpreting the examination. The sonologist should serve as the final checkpoint to identify if a patient who met the inclusion criteria for screening received the augmented maneuvers and include their observations and grading in the report. The panel acknowledged that there may be observations of DE at routine pelvic US in a patient who did not report any of the eligible history or symptoms. In this scenario, the recommendation is to report the observations with a suspicion of DE. Patients with a long history of contraceptive use may also have DE with minor or no symptoms (41,43,44). Augmented pelvic US may be indicated by other symptoms or history and may be performed at the discretion of the ordering or reading clinician.

Additional Imaging Techniques for Augmented Pelvic US

Recommendation: The panel unanimously agreed that an augmented pelvic US examination would have the greatest feasibility, acceptance, and impact in general US-based screening for DE.

Augmented pelvic US should include additional imaging focusing on the posterior compartment, the relative positioning of the uterus and ovaries, and the uterine sliding sign (transducer pressure or bimanual demonstration of uterine mobility).

Transvaginal evaluation is essential for screening detection of DE and transabdominal examination alone is insufficient. The panel recommends MRI when transvaginal imaging is not feasible and there is high clinical suspicion of endometriosis.

The panel recommended no bowel preparation for augmented pelvic US.

Routine pelvic US examinations are conventionally performed for all conditions requiring imaging of the pelvis. Minimum standard US views are mandated by multisociety practice guidelines but make no specific DE-focused imaging

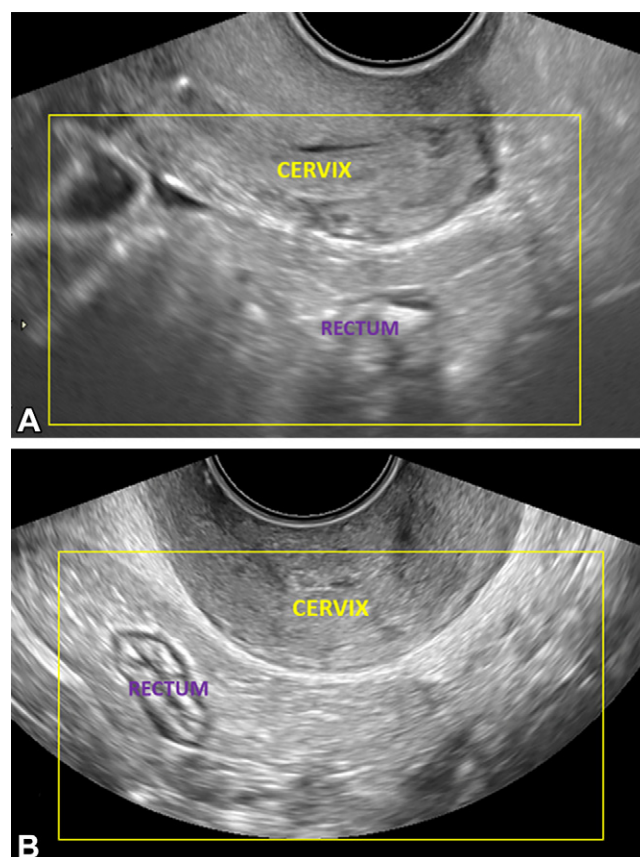


Figure 1: Transvaginal US images show the posterior compartment in a 25-year-old patient with dysmenorrhea, on the retrocervical field of view (area of interest outlined in yellow), 4–5-cm deep to the cervix. Longitudinal (A) and transverse (B) views. The transducer is in the anterior fornix. Longitudinal and transverse sweeps were acquired to include these areas.

recommendations (19,45). Institutional protocols vary, but the allotted time for these examinations typically ranges from 30 to 45 minutes. Augmented pelvic US focuses on transvaginal sonography of the posterior compartment to optimally assess the most common sites of DE (Fig 1). Dynamic maneuvers that use the real-time imaging capability of US, including a uterine sliding cine (Movies 1–3) and a sweep of the posterior compartment (which includes the torus uterinus and retrocervical space [including USLs]), parametrial, midrectal, and pararectal regions are recommended (Table 6, Movies 4–6). These are in addition to standard images obtained in accordance with the 2020 American College of Radiology, American College of Obstetricians and Gynecologists, American Institute of Ultrasound in Medicine, Society for Pediatric Radiology, and Society of Radiologists in Ultrasound practice parameter (19). Uterine position influences probe placement and image acquisition (Table 6).

Two-dimensional images may be obtained with a two- or three-dimensional transducer. Cine sweeps are preferred in addition to routine transverse and longitudinal static images of the uterus in routine pelvic US. If a cine sweep cannot be recorded or stored for review, representative static images should be stored and the sonographer should make a note of the uterine sliding sign as normal, abnormal, equivocal, technically inadequate, or not performed.

Table 6: Technical Recommendations for Augmented Pelvic US

Parameter	Recommended 2D Cine Sweep	Alternative Automated 3D Cine	Tips and Hints
Recommended additional imaging			
Uterine sliding maneuver			
Posterior fornix	Anteverted uterus: Obtain longitudinal uterine sliding cine angled toward the posterior cervix.		Does the cervix move relative to the rectum, perirectal adipose, other bowel, or posteriorly positioned ovaries?
Posterior fornix	Retroverted/retroflexed uterus: Obtain longitudinal uterine sliding cine centered at cervicouterine junction.		
Posterior compartment evaluation			
Anterior fornix	Anteverted uterus: Transverse cine sweep from the uterine fundus as far as possible inferiorly through the cervix. Longitudinal cine sweep of the uterus and cervix obtained angling as far laterally right and left as feasible. Include posterior compartment structures, 4–5 cm posterior to the uterus.	Initiate a transverse wide-field acquisition centered at the posterior cervicouterine junction. Initiate a longitudinal wide-field acquisition at the midline endometrium/endocervix. Include posterior compartment 4–5 cm deep to the uterus in anteverted uteri.	Are there any hypoechoic DE observations? Pay special attention to posterior uterine serosa in midline at level of cervicouterine junction, retrocervical space, anterior wall rectum, USLs. Assess ovaries for posterior or “kissing” position.
Posterior fornix	Retroverted/retroflexed uterus: Transverse cine sweep from the uterine fundus as far as possible through the cervix. Longitudinal cine sweep of the uterus and cervix obtained angling as far laterally right and left as feasible.		
Optional additional imaging			
Uterine sliding maneuver (alternative)			
Anterior fornix	Anteverted uterus: Longitudinal uterine sliding cine centered just inferior to the cervicouterine junction, transducer pressure on anterior cervix. Useful when posterior fornix transducer positioning is difficult or painful.		Does the cervix move relative to the rectum, perirectal adipose, other bowel, or posteriorly positioned ovaries?
Anterior compartment bladder sliding maneuver			
Anterior fornix	Longitudinal uterine sliding cine centered on the inferior aspect of the urinary bladder.		Does the bladder move relative to the uterus? Are there hypoechoic DE observations of the posterior bladder wall or in the space between the bladder and anterior uterine serosa?
Middle compartment (ovarian) sliding maneuver			
Anterior, lateral or posterior fornix	Transverse cine applying transducer pressure and/or manual pressure with the nonscanning hand over the ovary/adnexa to evaluate mobility. Longitudinal cine may also be useful.		Does the ovary move relative to the uterus, bowel, and pelvic side wall? Are there hypoechoic DE observations especially on the USLs or bowel, adhering the ovary to adjacent structures or the contralateral ovary?

Note.—DE = deep endometriosis, 3D = three-dimensional, 2D = two-dimensional, USL = uterosacral ligament.

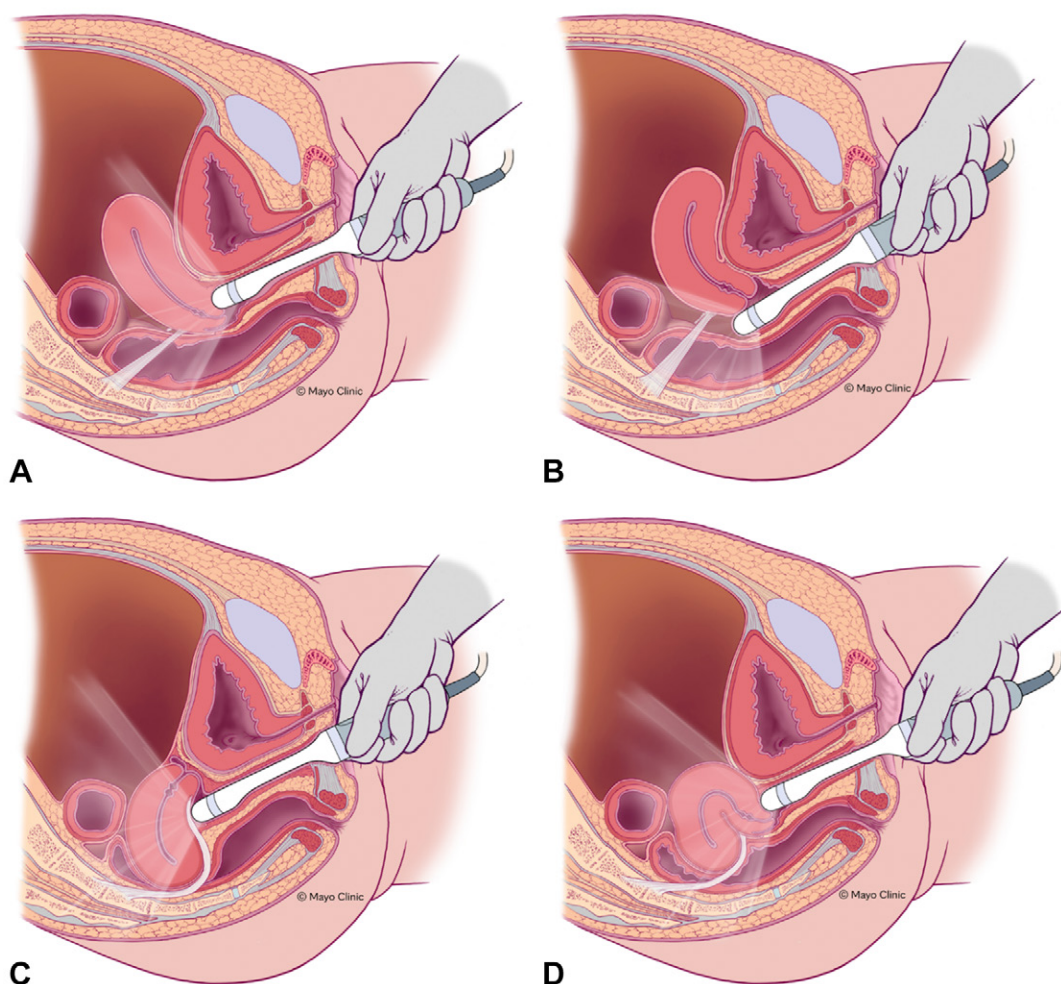


Figure 2: Illustration shows how to position the transvaginal sonography transducer based on uterine position and uterosacral ligament (USL) anatomy variations (light gray band). The relative relationship between the transducer, USLs, and cervicouterine junction is demonstrated for **(A)** anteverted uterus, anterior fornix transducer position; **(B)** anteverted uterus, posterior fornix transducer position; **(C)** retroverted uterus, posterior fornix transducer position; and **(D)** anteverted/retroverted uterus, anterior fornix transducer position. Reprinted, with permission, from reference 7.

A modest learning curve exists for the technical aspects of sliding maneuver and posterior compartment image acquisition and adequate imaging can be obtained by education and training (46,47). Attention to probe placement (Fig 2) and suggested imaging techniques can lead to high-yield imaging (Table 6).

Augmented pelvic US-based evaluation of uterine serosa.—

The panel recommends focusing special attention on the posterior uterine serosa during augmented pelvic US on static and cine images, which is a common site for endometriosis. Evaluation includes assessment for serosal implants that may mimic adenomyosis but extend inward from the uterine serosa toward the endometrium. This is in contradistinction to typical adenomyosis, which begins at the endometrial-myometrial junction and extends toward the uterine serosa.

Augmented pelvic US-based evaluation of retrocervical space.—Acquire static or preferably cine images focusing on the retrocervical region to assess for USL DE. There was a

unanimous consensus that imaging through the posterior fornix is favorable for DE evaluation regardless of the uterine version.

USL position varies depending on the uterine version. When feasible, reposition the transducer from the anterior vaginal fornix to the posterior vaginal fornix for optimal evaluation (37). In anteverted uteri, the retrocervical space may be imaged from both the anterior and posterior fornices (Table 6). The retrocervical space of interest is posterior and inferior to the cervicouterine junction in the anterior fornix view (Fig 1). On the posterior fornix view, the retrocervical space is in the near field and is immediately underneath the vaginal wall. The torus uterinus is an anatomic landmark located posterior to the cervicouterine junction where the uterine ends of the two USLs insert in the midline. Most retrocervical DE involves the area near the torus uterinus. Normal USLs appear as smoothly echogenic, homogeneous band-like structures angling laterally from just inferior to the cervicouterine junction (torus uterinus) (Fig 3) (48). If there is difficulty entering the posterior vaginal fornix, the area of the retrocervical space may also be

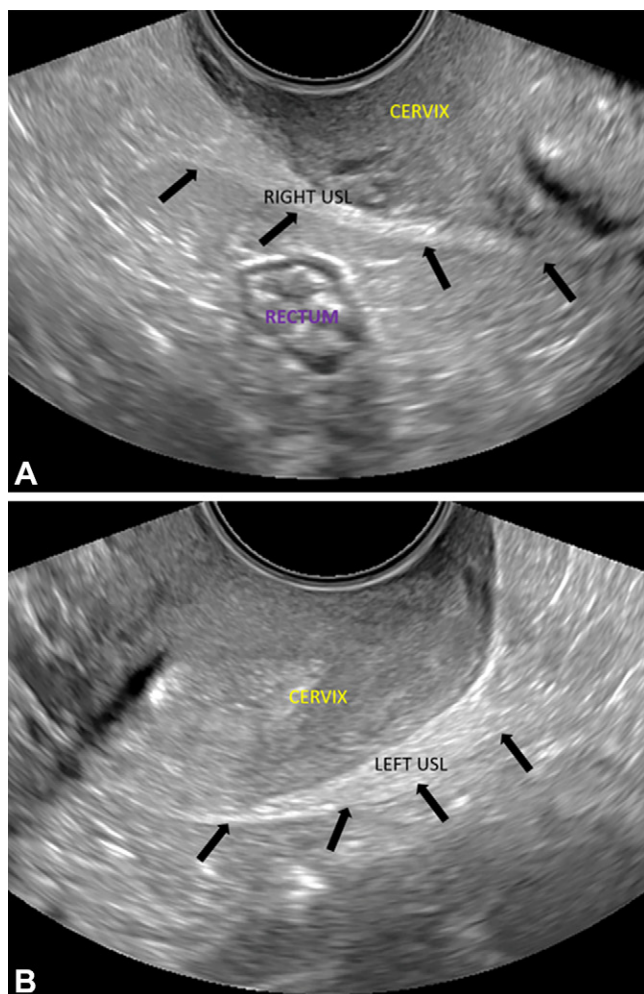


Figure 3: Transvaginal US in normal right and left uterosacral ligaments (USL) in a 32-year-old patient with chronic pelvic pain and echogenic bands insert near the posterior cervicouterine junction (arrows, **A** and **B**). Transverse oblique images show the **(A)** right and **(B)** left anterolateral fornices.

assessed by scanning transversely through the cervix from the anterior fornix. In this scenario, an echogenic band extending from the posterior cervical serosa and coursing laterally can be observed (Movie 7). Although confident identification of the USLs as a distinct echogenic band is possible on US, simply imaging through the retrocervical space is sufficient to observe DE, which frequently involves the USLs in this area.

In retroverted and most retroflexed uteri, longitudinal and axial sweeps are acquired from the posterior vaginal fornix only as the probe slides and naturally comes to lie in the posterior fornix with the retroverted uterus anatomy (Table 6, Movie 5). The retrocervical space will lie in the near field beneath the vaginal musculature in such individuals. Occasionally, in the setting of DE, the cervix will be anteverted and the uterus steeply retroflexed (question mark or horse-shoe-shaped uterus) (Fig 4). In such individuals, the transducer may be positioned in the anterior fornix and findings of retrocervical DE may be observed adhering the posterior cervix to the uterus and may involve the adjacent wall of the posterior vaginal fornix.

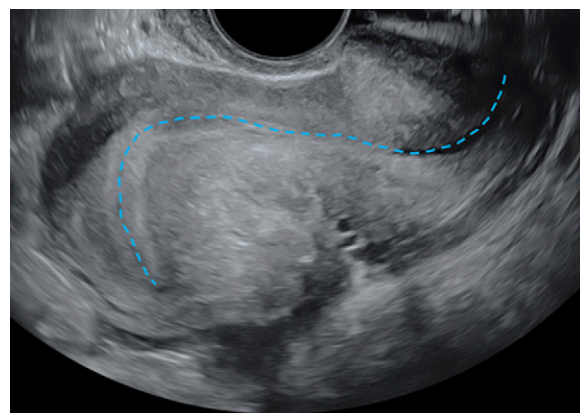


Figure 4: Transvaginal US in a 41-year-old patient with chronic pelvic pain and dyschezia shows the “question mark sign” uterine configuration. Longitudinal view shows an abnormal uterine configuration in which the uterus is sharply retroflexed because of deep endometriosis that is tethering the posterior cervix to the uterine corpus. This observation is usually identified by abnormal endometrial axis with sharp retroflexion of the uterine fundus (dashed blue line) and constitutes a category B (ie, indirect endometriosis) observation.

Uterine and ovarian relative positioning.—Two- and three-dimensional static and cine images may be acquired to help assess the relative positioning of the uterus and ovaries (Movies 4, 5). The panel advocated for but did not mandate the acquisition and review of cine clips to evaluate the pelvic anatomy whenever possible. Alternatively, when available, one may use a three-dimensional transducer to obtain rapid, standardized views, storing them as cine clips (Movie 6). Normally, ovaries are located at the sides of the uterus along the pelvic side walls. Evaluation for DE should include assessing the ovarian position and noting a location posterior to the uterus, adjacent to each other (ie, kissing ovaries configuration), near the cervix, or low in the posterior compartment. When a kissing ovaries configuration or abnormal ovarian position is noted, optional dynamic imaging can be performed by applying direct probe pressure with the intent to separate the ovaries and record the tethering of the ovaries to each other, the pelvic side wall, or the uterus (Movie 8).

When the ipsilateral ovary is retropositioned close to the cervix or cervicouterine junction, the retrocervical space should be assessed for DE. This is because adhesion of the ovary to DE in the USL in the retrocervical space is a common cause of retropositioned ovary, especially in the presence of an endometrioma. Careful interrogation of the edge of the malpositioned ovary or endometrioma may reveal adjacent solid tissue outside the ovary, which is typically DE on the USL. Bilateral retrocervical DE is common when both ovaries are retropositioned and in contact with each other (kissing ovaries) (Fig 5). In such individuals, the anterior rectal wall should be carefully reviewed for serosal or muscularis DE observations, preferably identified on cine clips (29). Adhesions present as hypoechoic bands and lines between DE implants and adjacent structures. Adhesions to the rectosigmoid wall, even in the absence of an invasive bowel observation, are often recognized by tenting of the bowel wall toward the torus uterinus with or without a retrocervical DE observation (Movie 9).

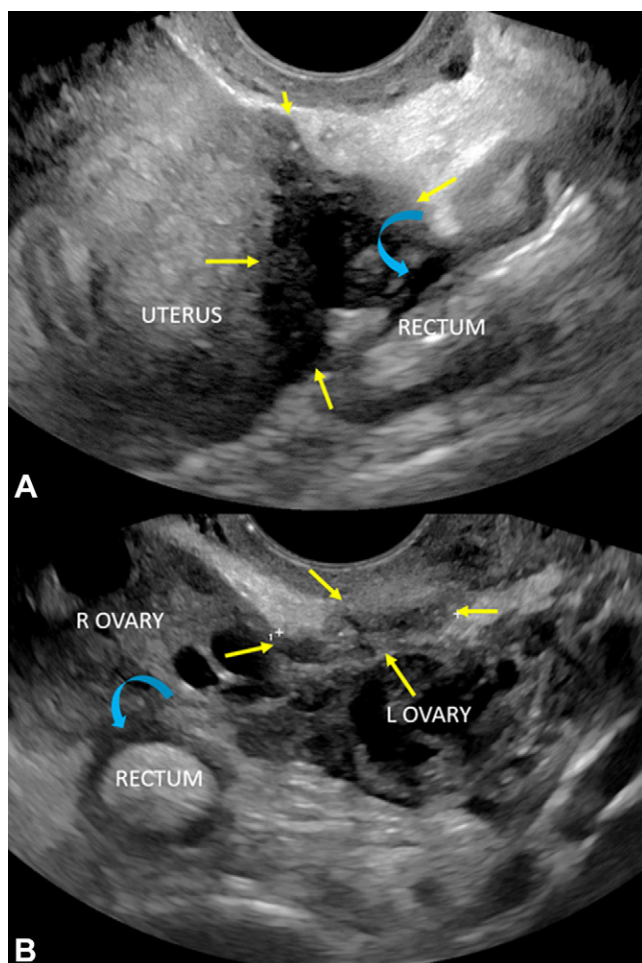


Figure 5: Transvaginal US through the posterior fornix in a 43-year-old patient with deep dyspareunia. Serosal adhesions to the adjacent rectum are shown (curved blue arrows). **(A)** Longitudinal and **(B)** transverse views show kissing ovaries without endometriomas, a category B (indirect endometriosis) observation. Deep endometriosis of the torus uterinus and posterior uterine serosa is shown (yellow arrows, **A** and **B**), a category A (direct endometriosis) observation. L = left, R = right.

Evaluation of uterine sliding sign.—The sliding maneuver should be performed to evaluate adhesions in the posterior cul-de-sac and represents an integral component of augmented pelvic US. The uterine sliding maneuver increases the detection of DE-related pouch of Douglas obliteration on US (49,50). The sonographer should explain to the patient the pushing technique and its clinical importance in diagnosing endometriosis before proceeding and remain cognizant of and responsive to patient discomfort. In anteverted uteri, preferably obtain the sliding maneuver from the posterior fornix view with the transducer pressure technique (Movies 1, 2). If there is difficulty placing the transducer in the posterior fornix, it is possible to obtain a cine of the sliding maneuver from the anterior fornix (Movie 3). In this situation, it is important to place enough pressure inferiorly on the cervix to create a clear slide between the uterus and posterior compartment structures. Avoid merely compressing the posterior compartment structures through the uterus. Always focus attention on the posterior cervicouterine junction. If the transducer push is equivocal, consider using the illustrated bimanual technique (Fig 6). In retroflexed and retroverted uteri, the sliding cine is best obtained by pressing with steep posterior angulation in the posterior fornix and then quickly releasing transducer pressure, looking for mobility between the cervix and retrocervical perirectal adipose or physiologic fluid pooling in the retrocervical area (Movie 2) (37). An absence of sliding is an indicator of posterior cul-de-sac adhesions (49).

Sonologists can apply the sliding maneuver to the anterior and middle compartments, including the vesicouterine space and ovaries (Movies 8, 10). The panel does not mandate these optional views because of the time constraints of augmented pelvic US. Immobility of the ovary relative to the uterus, pelvic sidewall, bowel, or contralateral ovary can be demonstrated, which is a useful indirect observation of endometriosis (35,51,52). Focused evaluation on the areas of tethering may

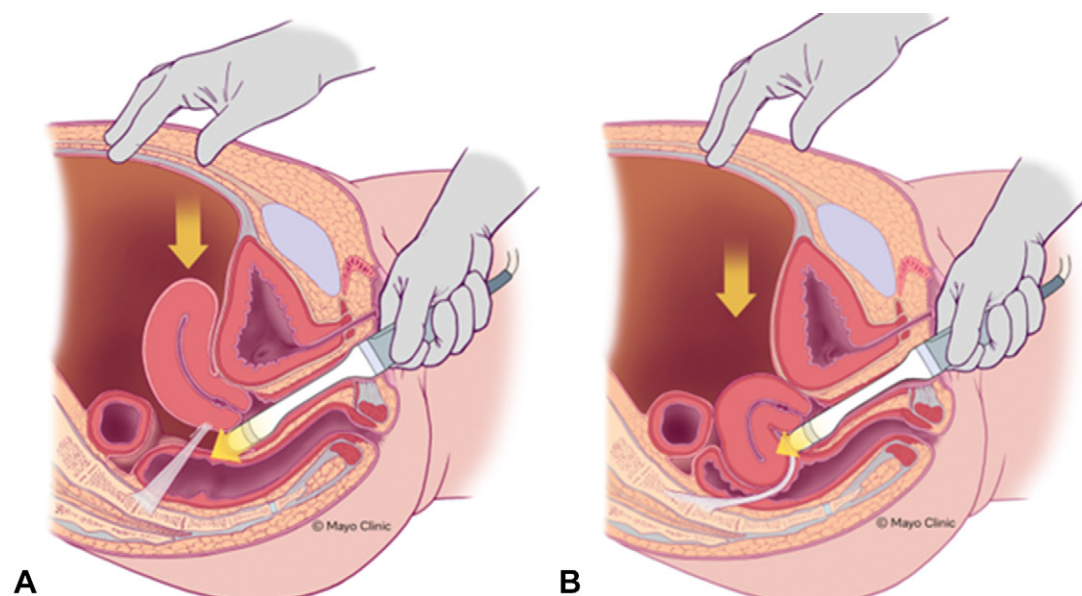


Figure 6: Illustration shows the uterine sliding maneuver, posterior fornix transducer position, anteverted uterus **(A)** and retroflexed uterus **(B)**. Adapted, with permission, from reference 7.

Table 7: Direct and Indirect US Observations in Deep Endometriosis

Category and Observation	Reference No.
Category A: direct endometriosis observation	
Ovarian endometrioma	76
DE implant of the uterine serosa with an outside-in pattern	77
Retrocervical DE (torus uterinus and/or USL) implant	20,25,27,28
Bladder DE implant in posterior location involving the detrusor muscle	20,24–26
DE implant in the uterovesical space	78
Rectovaginal space or rectovaginal septal DE implant	21,25
Rectosigmoid hypoechoic DE implant with tapering ends (other descriptors: Comet tail sign)	5,20,27,29,30
Category B: indirect endometriosis observation	
Fixed uterine retroflexion	79,80
Bowel tethering to posterior uterus without discrete endometriosis implant in the absence of PID symptoms, inflammatory bowel disease, or prior myomectomy	79–81
Kissing ovaries without ovarian endometriomas	64
Unilateral or bilateral posterior ovarian location in proximity to the cervix/retrocervical space without endometrioma	81
Ovarian immobility if incidentally observed on uterine sliding maneuver without endometrioma	82
Category C: endometriosis-associated observation	
Adenomyosis, typical (nonspecific)	83
Hydrosalpinx (nonspecific)	84
Hematosalpinx (infrequently isolated, differentiate clinically from pyosalpinx)	84

Note.—DE = deep endometriosis, PID = pelvic inflammatory disease, USL = uterosacral ligament.

depict direct DE observations. Similarly, the panel encourages but does not mandate ovarian mobility assessment, especially when other endometriosis features are observed. The panel notes that ovarian tethering and fixation is sometimes incidentally observed during the uterine sliding maneuver and should be reported when present.

The role of color Doppler.—Color Doppler imaging of the adnexa is routinely performed and should be done so in compliance with societal guidelines. The panel made no specific recommendations regarding color Doppler imaging for DE and deferred to previously published guidelines (19). Color Doppler imaging can help assess solid-appearing elements in suspected endometriomas. Color Doppler is not necessary for identifying or categorizing DE observations, which are typically hypovascular.

Evaluation of the anterior compartment and urinary bladder.—The panel did not make any specific recommendations about imaging the anterior compartment and urinary bladder. The anterior compartment is the least common site of pelvic DE involvement. Therefore, the panel recommended that the augmented maneuvers focus on the posterior compartment where DE most frequently occurs. Images of the urinary bladder can either be acquired transabdominally or transvaginally as a part of the routine pelvic US and reviewed for the presence of nodularity, particularly at the vesicouterine space and posterior bladder wall. Although uncommon, US has been reported to distinguish bladder endometriosis with high accuracy (18,26,53).

US-based Observations and Interpretation for Endometriosis: Direct and Indirect Observations

Recommendation: Assess direct and indirect observations during augmented pelvic US.

The panel considered the results from the literature search, including published sensitivity and specificity data (Table 6), along with expert opinion, and reached a consensus on direct and indirect imaging observations of DE (Table 7).

Endometriosis implants are typically hypoechoic with punctate echogenic foci. These may have regular, irregular, lobulated, or stellate margins. Linear hypoechoic bands of tissue may be observed extending peripherally from the implants secondary to surrounding fibrosis. Vascularity at color Doppler imaging is variable, and DE implants are usually hypovascular. Specific imaging observations vary by location.

We organized endometriosis observations into categories based on the highest association with DE (Table 7).

Category A: Direct endometriosis observations.—Direct observations result from the presence of ectopic endometrial glands and/or stroma outside the uterus. These include ovarian endometriomas and DE observations in characteristic, commonly encountered locations on pelvic US, such as posterior uterine serosa, retrocervical space and USLs, rectovaginal space, rectosigmoid colon, posterior bladder, or uterovesical space.

Ovarian endometriomas: Ovarian endometriomas are typically benign, cystic ovarian lesions with low-level, homogeneous (ground glass) internal echoes and no internal vascularity (Fig 7). Any solid-appearing areas should be evaluated with color Doppler,

optimizing color scale and gain. Vascularized solid components should be noted owing to the risk of clear cell and endometrioid carcinomas (54). The risk of ovarian cancer in patients with endometriosis is 1.9%, compared with 1.3% for the general population (55–57). When solid or solid-appearing components are noted, the panel recommends characterizing lesions with the US Ovarian and Adnexal Risk Stratification System (58,59).

Uterine serosal DE: The posterior uterine serosa is commonly involved with posterior compartment DE, where uterine implants manifest as ill-defined hypoechoic observations, with

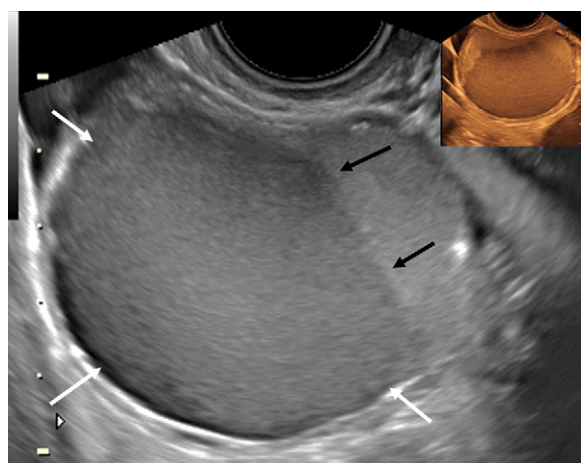


Figure 7: Transvaginal longitudinal US scan in a 31-year-old patient with deep dyspareunia shows an endometrioma with homogeneous low-level (ground glass) echoes (white arrows) and fluid-fluid level (black arrows). Se-pia inset in transverse view shows similar observations, a category A (direct endometriosis) observation. Adapted, with permission, from reference 7.

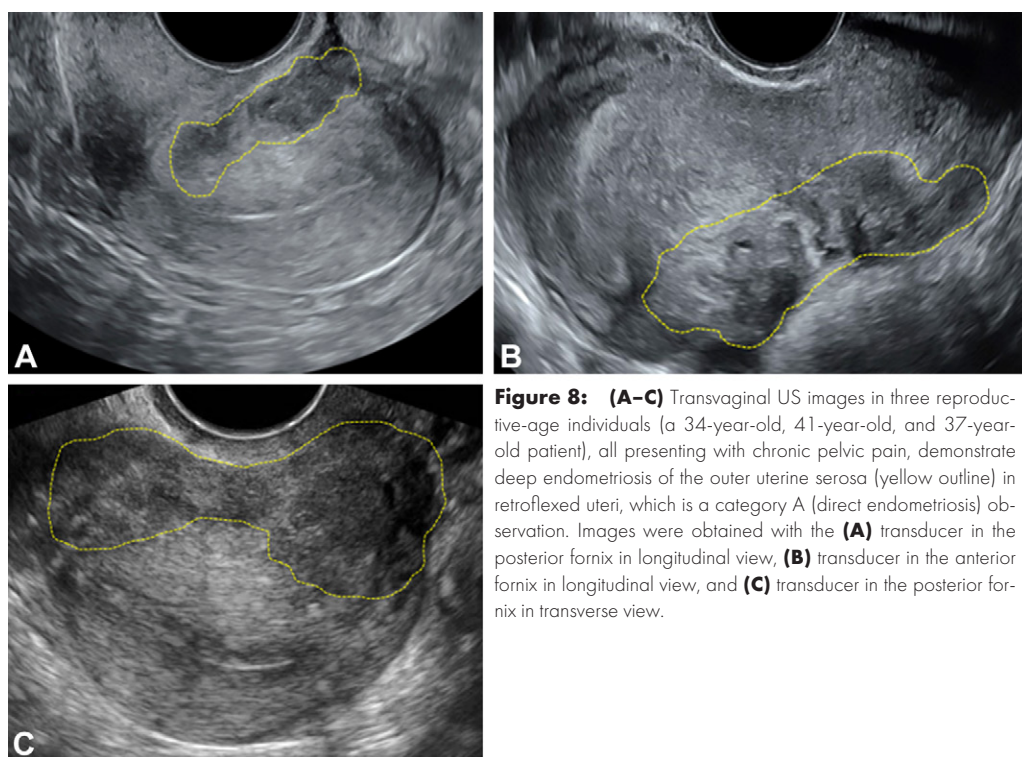


Figure 8: (A–C) Transvaginal US images in three reproductive-age individuals (a 34-year-old, 41-year-old, and 37-year-old patient), all presenting with chronic pelvic pain, demonstrate deep endometriosis of the outer uterine serosa (yellow outline) in retroflexed uteri, which is a category A (direct endometriosis) observation. Images were obtained with the (A) transducer in the posterior fornix in longitudinal view, (B) transducer in the anterior fornix in longitudinal view, and (C) transducer in the posterior fornix in transverse view.

internal echogenic foci and cystic areas. The pattern is an extension of DE from the outer myometrial serosa with an outside-to-inside pattern (Fig 8). This is a direct observation of DE and should be differentiated from typical adenomyosis, which extends from the endometrial-myometrial junction outward toward the uterine serosa (60). The panel recommends not using terms such as *adenomyosis externa* or *focal adenomyosis of the outer myometrium* to clarify the distinct pathophysiology of the two processes.

Retrocervical DE (including USLs): Retrocervical DE typically occurs near the posterior aspect of the cervix, where USLs insert, extending laterally and posteriorly within the posterior compartment. Retrocervical DE usually manifests as hypoechoic observations that may be smooth, irregular, or spiculated. Punctate echogenic foci are common. Cystic foci are less common. The midline retrocervical USL insertion site, the torus uterinus, is frequently involved (Fig 9). Adhesions to one or both ovaries may be assessed and adhesions to the adjacent rectum are frequently observed, often with distortion of the rectal wall toward the retrocervical observation (Fig 10) (48,51).

Bladder and vesicouterine space endometriosis: Bladder endometriosis manifests as an isoechoic or hypoechoic, smooth or irregular, elongated or spherical mass invading the detrusor muscle, often at the base or dome (Fig 11). Such observations may or may not protrude into the bladder lumen and may be cystoscopically occult (61,62). These observations can be contiguous with DE in the vesicouterine space.

Rectosigmoid endometriosis: Bowel endometriosis manifests as solid and markedly hypoechoic elliptical, C-shaped, or Ω-shaped thickenings of the bowel wall with tapering ends (Fig 12, Movie 9) (37,63). Observations occasionally exhibit high-contrast internal echoes. Cystic components are rare. Depth of invasion can be predicted based on lesional thickness and obliteration of expected anatomic interfaces (60). Invasion of the mucosa is rare. Therefore, colonoscopy rarely directly shows such lesions. In the rectum, implants begin on the anterior wall because of the anterior wall's exposure to the serosa of the posterior compartment. Rectal DE implants are frequently associated with retrocervical or USL DE. Multiple bowel implants

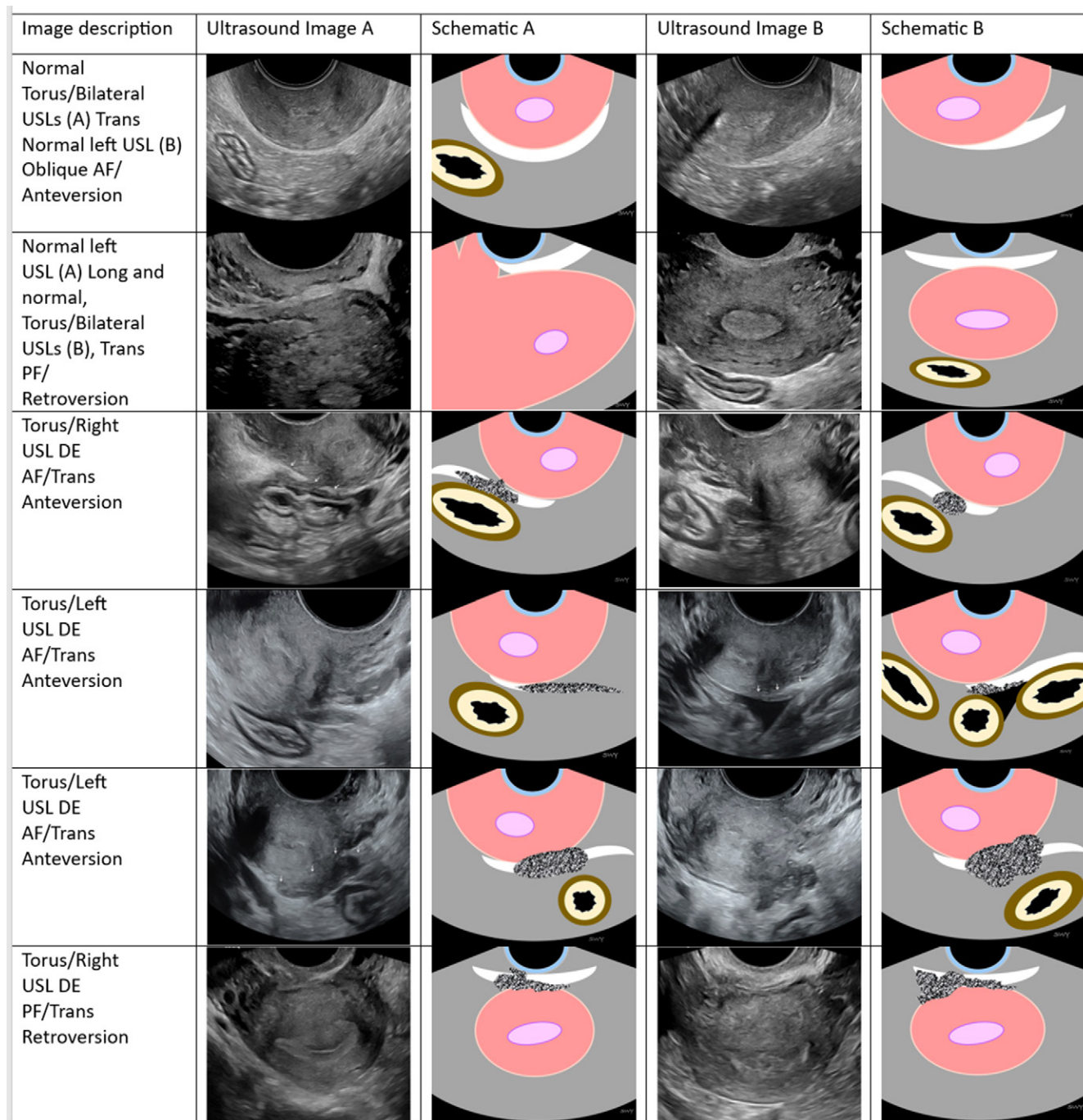


Figure 9: Transvaginal US posterior compartment deep endometriosis (DE) image gallery of reproductive age individuals (19–48 years) with chronic pelvic pain, deep dyspareunia, dyschezia, dysmenorrhea, or infertility demonstrates the spectrum of common DE observations with schematics and color legend. US images in columns A (Ultrasound Image A) and B (Ultrasound Image B) are examples of similar observations in multiple patients (*Fig 9 continues*).

are common. Whereas sonography is excellent for the full depiction of bowel implants, such depiction is beyond the scope of augmented pelvic US. The consensus panel recommends advanced endometriosis imaging (expert US or expert MRI) for bowel endometriosis mapping (4,6,13).

Vaginal DE: Vaginal DE usually manifests in the posterior apex with moderately hypoechoic echotexture similar to retrocervical or USL DE. Vaginal DE is commonly confluent with USL

and/or adjacent rectal DE implants (Movie 11). Cystic areas are sometimes present.

Category B: Indirect endometriosis observations.—Indirect observations are associated findings or sequelae of endometriosis present at imaging without direct visualization of DE implants. These include observations commonly encountered with DE, such as fixed uterine retroversion, abnormal ovarian location or mobility, and tethering of bowel loops to the

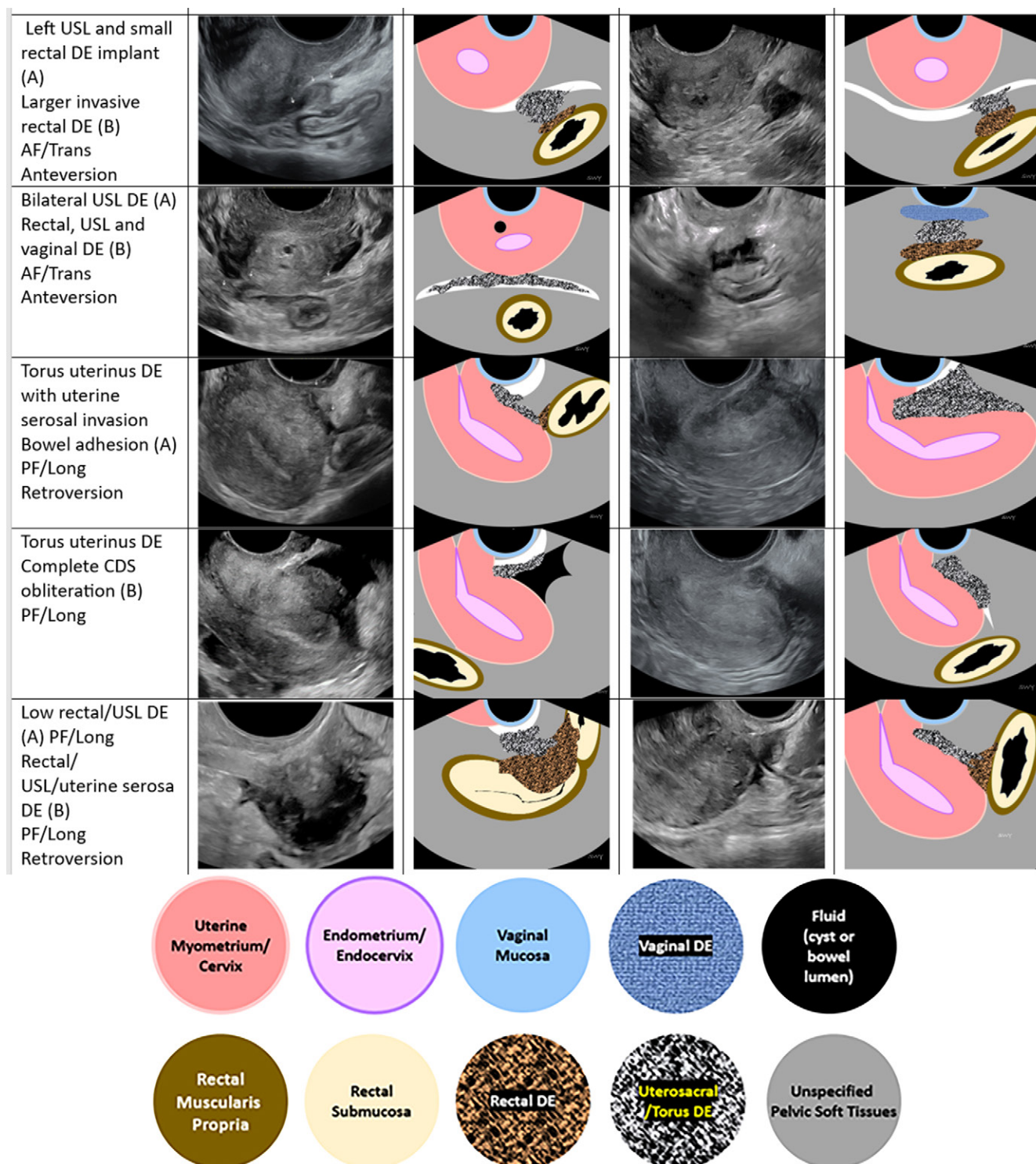


Figure 9 (continued): Anteversion and retroversion refer to uterine position. AF = anterior fornix transducer position, CDS = cul-de-sac, PF = posterior fornix transducer position, Long = longitudinal view, rans = Transverse view, USL = uterosacral ligament.

posterior uterus but without an observation of DE. The existing literature regarding the sensitivity and specificity of these observations is sparse. The identification and recommendations are, therefore, based on expert consensus.

Fixed uterine retroversion: A retroflexed uterus that remains in this position even with direct transducer pressure may be associated

with DE from endometriotic adhesions between the cervix and uterus or adhesions between the rectum and uterine fundus. In severe cases, the uterus may be sharply retroflexed or appear in a question mark or horseshoe-shaped configuration.

Bowel tethering to the posterior uterus: Scarring from DE can cause tethering of bowel loops to the posterior uterus. However,

when there is no observation of DE, it is essential to exclude other causes of fibrosis and adhesions such as pelvic inflammatory disease, inflammatory bowel disease, and prior pelvic surgery. One may optionally perform a dynamic evaluation with probe pressure to separate the areas of potential tethering.

Abnormalities of ovarian position and mobility: Retropositioned or kissing ovaries, in which the ovaries are posteriorly and medially located behind the uterus, can occur in DE, even in the absence of endometrioma. The likelihood of advanced-stage endometriosis is eight times higher with kissing ovaries than with normally positioned ovaries, regardless of the presence of an endometrioma at MRI (64). Abnormal ovarian location may be further evaluated for immobility with direct probe pressure or may be observed during the performance of the uterine sliding maneuver.

Category C: Endometriosis-associated observations.—These observations are associated with endometriosis but are not always a direct result of DE or are observed infrequently in isolation, and include adenomyosis, hydrosalpinx, and hematosalpinx.

Adenomyosis: Historically, features of adenomyosis have been found at transvaginal US in 21%–42% of patients undergoing surgery for endometriosis (65). More recently, it has been reported that 53% of patients with ovarian endometrioma (38) and 89% of patients undergoing laparoscopic surgery for endometriosis had observations for adenomyosis at imaging (66).

The Morphological Uterus Sonographic Assessment group has recently classified direct and indirect imaging features of adenomyosis (67). Direct features are myometrial cysts, hyperechoic islands, and echogenic subendometrial lines and buds. Indirect features are a globular uterus, asymmetric myometrial thickening, fan-shaped shadowing, translesional vascularity, irregular junctional zone, and interrupted junctional zone. Adenomyomas are recognized as focal observations with characteristics of adenomyosis that create myometrial asymmetry, have ill-defined borders, and translesional vascularity without a mass effect

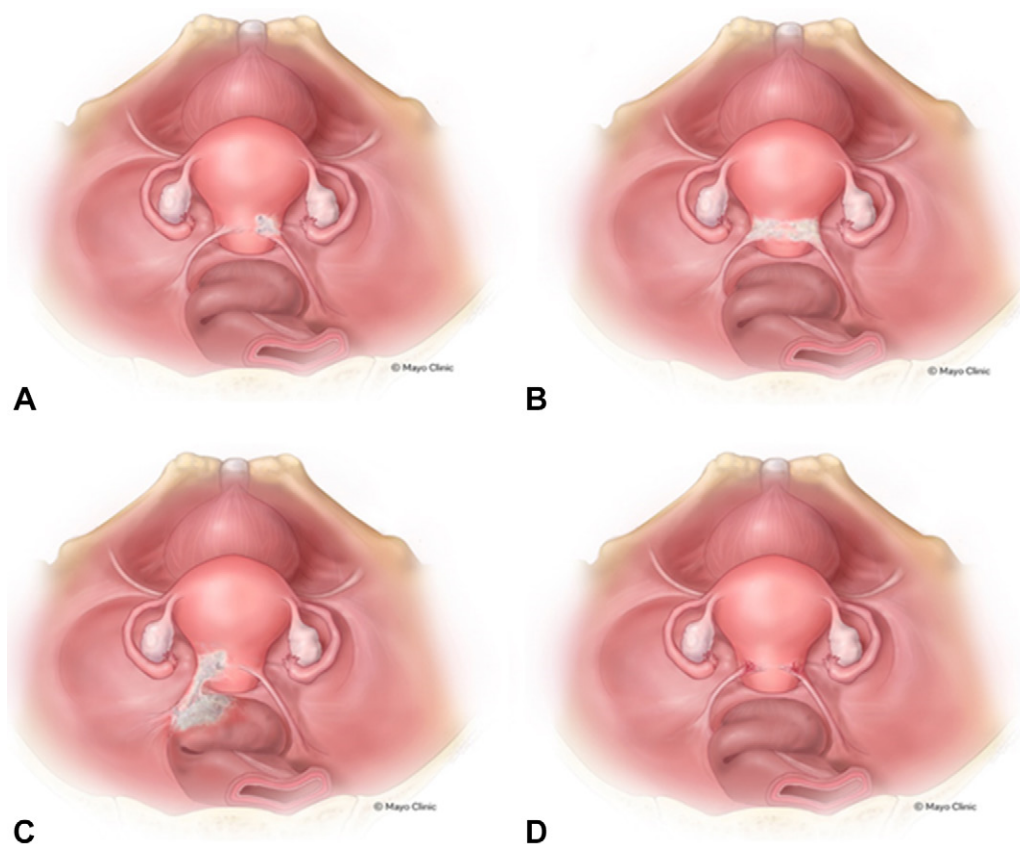


Figure 10: Laparoscopic view illustrations of common posterior compartment deep endometriosis (DE) and superficial endometriosis patterns. **(A)** Unilateral DE in right uterosacral ligament (USL)/torus uterinus. **(B)** Bilateral USL/torus uterinus DE. **(C)** Left USL and rectal DE with thickening and retraction of rectal wall toward the torus uterinus. **(D)** Bilateral USL and torus uterinus DE. Reprinted, with permission, from reference 7.

on myometrial vessels. Sharply circumscribed borders, edge-refractive shadows, and circumferentially deviated myometrial vessels suggest the alternative diagnosis of leiomyoma (68). Because the spectrum of adenomyosis observations is variable, and given the high prevalence of the disease, this panel does not recommend advanced endometriosis imaging based solely on the observation of typical, inner myometrial adenomyosis.

Hydrosalpinx and hematosalpinx: Hydrosalpines may be observed in endometriosis either by direct involvement or adhesions. Hydrosalpines are tubular, cystic areas separate from the ovary. Incomplete septations, waist-sign, endosalpingeal folds or ridges, and chains of cysts are common features (58,69). The presence of low-level internal echoes is suggestive of hematosalpinx. In the absence of clinical signs of infection or ectopic pregnancy, hematosalpinx may be an indicator of endometriosis in the fallopian tube. In the panel's expert opinion, the multifactorial etiology of hydrosalpinx makes this observation too nonspecific to warrant further evaluation for endometriosis when seen in isolation. Because of the difficulty distinguishing pyosalpinx from hematosalpinx at imaging and the infrequent isolated finding of hematosalpinx in patients with endometriosis, isolated hematosalpinx was deemed too infrequent to prompt advanced endometriosis imaging in the absence of high clinical concern.

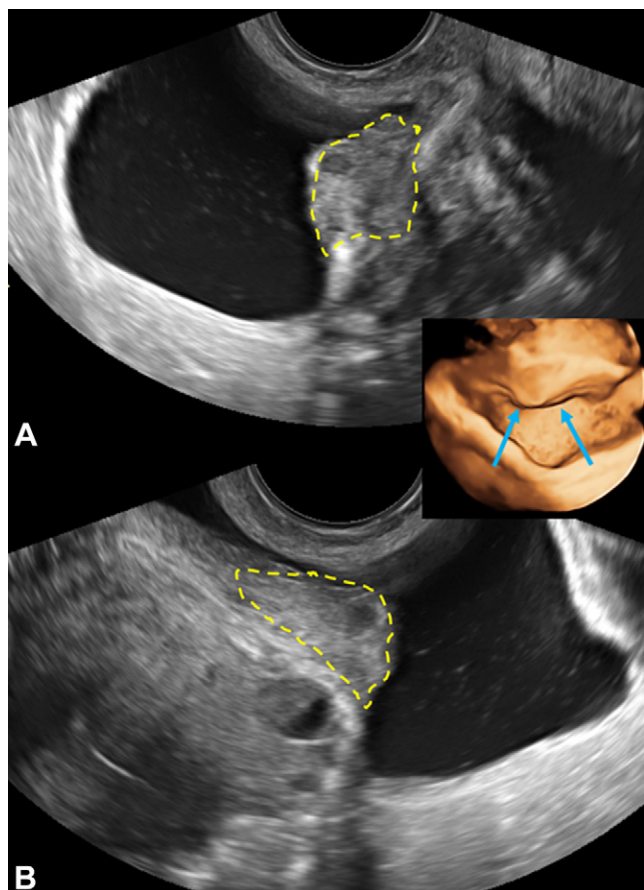


Figure 11: Transvaginal US images of bladder endometriosis in a 31-year-old patient with dysuria shows a midechogenicity nodule (yellow outline) extending from vesicouterine space into the detrusor muscle, longitudinal (A) and transverse (B). Three-dimensional US virtual cystoscopic view is shown (inset, arrows). This is a category A (direct endometriosis) observation.

Reporting Augmented Pelvic US for Endometriosis and Follow-up Recommendations

The panel recommendations for reporting and follow-up of endometriosis (Table 8) are based on the literature review and expert consensus in the instance of limited or no data, which pertains predominantly to indirect observations (category B) and endometriosis-associated observations (category C). Appropriate follow-up imaging and clinical recommendations are provided for each category. The purpose is to capture a greater spectrum of disease presentations at US, but future research validation is needed.

Recommendation: Reporting for augmented pelvic US examinations should include the following four categories: Incomplete (APU-0), normal (APU-1), equivocal (APU-2), and positive (APU-3), where APU indicates augmented pelvic US (Table 8).

Any single direct imaging observation (category A) of endometriosis should lead to endometriosis diagnosis, a recommendation for advanced endometriosis imaging, and referral to a reproductive endocrinologist or gynecologic surgeon familiar with DE, as appropriate. In the absence of category A observations, findings are suggestive of endometriosis when two or more indirect observations (category B) or one category B and one

endometriosis-associated observation (category C) are noted. Referral to gynecology for further evaluation and possible advanced endometriosis imaging is recommended. When only category C observations are present, a gynecology referral is appropriate. Given the nonspecific nature of these observations, advanced endometriosis imaging is usually not recommended but may be performed if there is high clinical suspicion of endometriosis.

Advanced endometriosis imaging consists of either expert US-based mapping of endometriosis following a prescribed pattern of search (4,6,7,13) and/or endometriosis-specific MRI with expert interpretation (32,59). The International Deep Endometriosis Analysis protocol or a similar protocol can be adopted for expert advanced US (13). Given large regional differences in training and credentialing criteria, like the Ovarian-Adnexal Reporting and Data System (O-RADS), emphasis is placed on the importance of experience in the accurate assessment of endometriosis (70). Examples include involvement in quality assurance activities and specialty conferences (ie, multidisciplinary and quality assurance conferences, gynecology and minimally invasive surgery correlation conferences, and gynecologic-oncology tumor boards) which typically denote a higher level of investment in the radiology-pathology correlation, a noteworthy aspect of specialization as it relates to endometriosis. The Society of Abdominal Radiology or European Society of Urogenital Radiology guidelines are suggested templates that can be followed for expert MRI review (32,70).

Structured reporting improves clarity, completeness, and compliance (71,72). Reporting adnexal lesions using the American College of Radiology O-RADS US Risk Stratification Lexicon and Management System is recommended. Endometriomas smaller than 10 cm and without solid components are characterized as O-RADS US 2 (almost certainly benign) (58).

Features of adenomyosis should be reported as present or absent using the descriptors from the Morphological Uterus Sonographic Assessment group (67). A summary opinion regarding the likelihood of adenomyosis should be given based on the observations, either absent/unlikely, possible, or very likely/definite. The location and approximate size of adenomyomas should be described, including the presence of serosal involvement.

When indicated, the uterine sliding sign should be reported as normal, abnormal, equivocal, technically inadequate, or not performed. The quality and confidence assessments are subjective, and confidence is expected to increase over time. The learning curve for performance and off-line interpretation of uterine sliding, as well as most aspects of DE assessment, is around 40 cases (47,73,74). Patient obesity and inadequate or improperly directed compression of the tissues may impair sliding sign assessment. One may observe normal sliding in cases of incomplete posterior compartment obliteration (75). An example of structured reporting for augmented pelvic US is provided in Appendix S2 and Movie 12.

Conclusion

Endometriosis is a common condition with substantial diagnostic delay, leading patients to experience pain, infertility, lost wages, and interrupted relationships. US is the

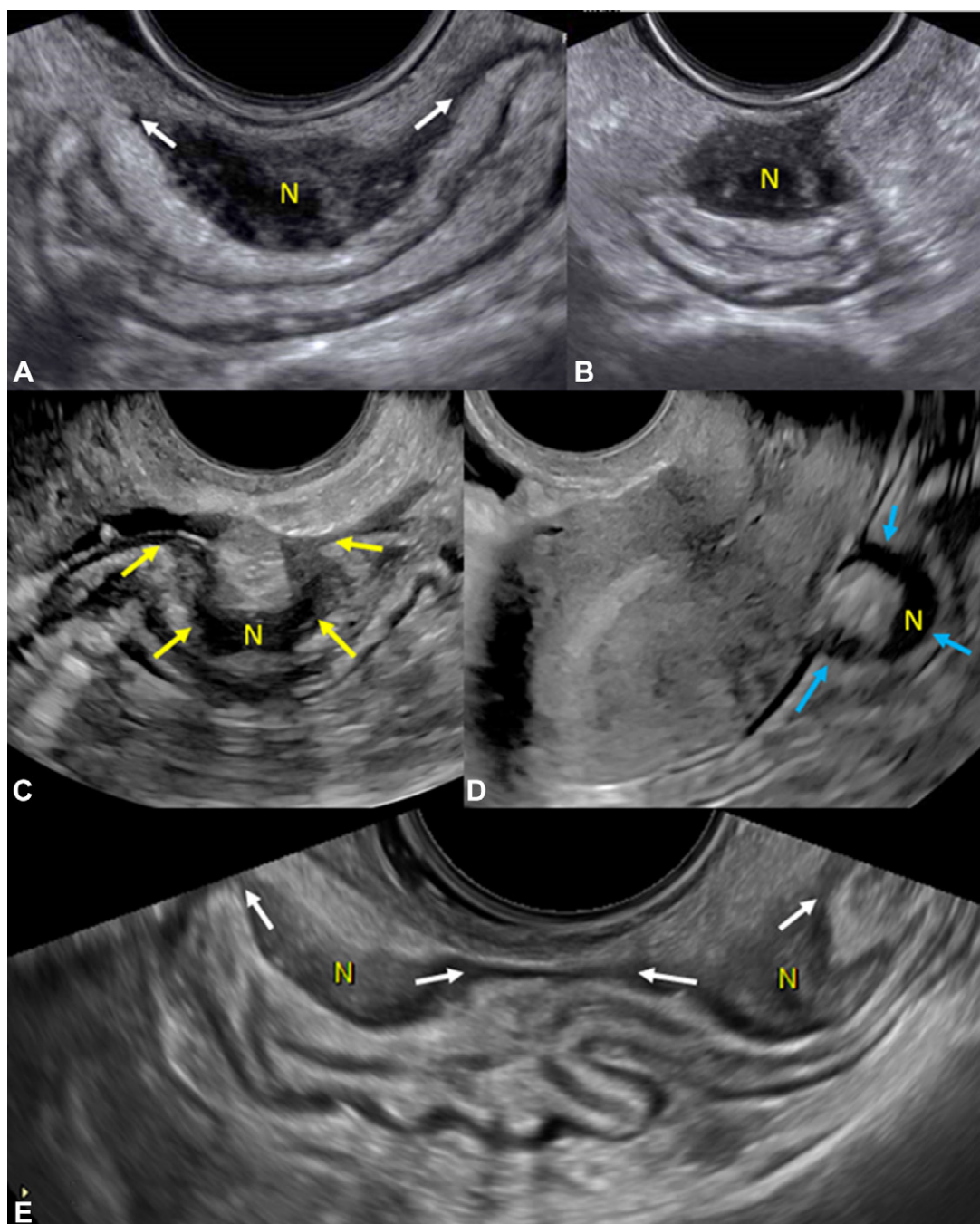


Figure 12: Transvaginal US shows deep endometriosis (DE) nodules (N) in the rectosigmoid colon. **(A)** Image in a 31-year-old patient with dyschezia shows an elliptical DE with tapering ends (arrows), longitudinal posterior fornix. **(B)** Transverse image of nodule in **(A)**, posterior fornix. **(C)** Image in a 27-year-old patient with chronic pelvic pain shows an Ω -shaped DE nodule in midrectum, longitudinal posterior fornix (arrows). **(D)** Image in a 33-year-old patient with deep dyspareunia shows a C-shaped nodule in midrectum, longitudinal anterior fornix (arrows). **(E)** Image in a 40-year-old patient with chronic pelvic pain shows tandem nodules of rectosigmoid colon with tapering ends (arrows), longitudinal posterior fornix. These are category A (ie, direct endometriosis) observations.

first-line imaging modality to evaluate pelvic pain. The Society of Radiologists in Ultrasound consensus regarding routine pelvic US for endometriosis aims to enhance deep endometriosis (DE) detection even at an initial US and with minimal additional time during imaging and no special patient preparation. Focusing imaging on anatomic regions where DE is common can increase detection of DE and decrease diagnostic delay.

These guidelines are meant for symptomatic patients (ie, pain and infertility) at typical risk for endometriosis. Patients at high risk for endometriosis because of prior diagnostic or therapeutic laparoscopy for endometriosis or strong clinical indications may benefit from proceeding directly to advanced endometriosis imaging, particularly if they are likely to undergo surgery or if monitoring is needed in the setting of infertility and medical treatment.

Table 8: Augmented Pelvic US Reporting for Endometriosis: Diagnostic Categories, Imaging Criteria, and Management Recommendations

Diagnostic Category	Description	Management	
		Clinical	Imaging
APU-0: Incomplete	Unable to perform TV US, cine sweeps, or uterine sliding maneuver; technically inadequate; patient factors impacted imaging (eg, extensive fibroids, nonvisualization of one or both adnexa)	Symptom management	Repeat augmented pelvic US or advanced endometriosis; Imaging may be considered on an individualized basis
APU-1: No imaging evidence of endometriosis	No direct (category A) or indirect (category B) observations	Symptom management	Imaging follow-up based on other nonendometriosis observations (eg, follow-up of any endometriosis-associated observation [category C] or concomitant pelvic pathology); absence of imaging features does not exclude endometriosis; advanced endometriosis imaging may be considered on an individual basis
APU-2: Equivocal for endometriosis	Only 1 category B observation	Symptom management; gynecology referral with optional referral to a deep endometriosis specialist and consideration of endometriosis surgery, minimally invasive gynecology surgery, and/or reproductive endocrinology consultation, based on patient goals of care	Imaging follow-up based on other nonendometriosis observations; advanced endometriosis imaging can be considered on an individual basis or whenever surgery is planned
APU-3: Positive for endometriosis	Any category A observation, two category B observations, or one category B observation with one category C observation	Symptom management; gynecology referral to endometriosis specialist, consideration of endometriosis surgery, minimally invasive gynecology surgery, and/or reproductive endocrinology consultation, based on patient goals of care	Recommend further evaluation with advanced endometriosis imaging

Note.—APU = augmented pelvic US, TV = transvaginal.

This consensus is based on expert opinion and review of the literature. Therefore, validation studies will be necessary to prove the accuracy of augmented pelvic US in widespread clinical application. Additionally, continuing education for sonographers, gynecologists, and radiologists regarding recognition of common observations of deep endometriosis (DE) and the applicability of augmented pelvic US with additional maneuvers and advanced endometriosis imaging will be paramount. The quality of advanced imaging protocols and equipment as well as the expertise of interpreting physicians for advanced endometriosis imaging and laparoscopy is also important for confirming the diagnosis of endometriosis. Accurate diagnosis requires recognition of tissue distortion and an intense, prescribed search pattern that leverages knowledge of common DE sites and associated observations. Laparoscopic surgery alone is recognized as an insufficient

standard for the diagnosis of DE, with many DE sites that are occult or suboptimally accessible at laparoscopy without preoperative imaging and knowledge of their location (71). Robust communication with minimally invasive gynecologic surgeons is key and multidisciplinary discussions can lead to incremental benefit for patients. The consensus panel is confident about the feasibility of simple additional maneuvers to improve endometriosis detection in this traditionally underdiagnosed condition.

Acknowledgment: The Society of Radiologists in Ultrasound panel acknowledges the valuable contributions to the consensus panel of Beryl Benacerraf, MD, prior to her death in October 2022. She was a professor of obstetrics, gynecology, and reproductive biology and radiology at Harvard Medical School and Brigham and Women's Hospital.

Author contributions: Guarantors of integrity of entire study, S.W.Y., P.J., L.C., M.M.H., Y.G., E.M.H., S.E., W.V.B.; study concepts/study design or data

acquisition or data analysis/interpretation, all authors; manuscript drafting or manuscript revision for important intellectual content, all authors; approval of final version of submitted manuscript, all authors; agrees to ensure any questions related to the work are appropriately resolved, all authors; literature research, **S.W.Y., P.J., L.C., S.R., R.M.K., M.M.H., P.G., M.F., Y.G., S.L.Y., L.P.**; clinical studies, **P.J., M.M.H.**; experimental studies, **E.M.H.**; statistical analysis, **P.J.**; and manuscript editing, all authors

Disclosures of conflicts of interest: **S.W.Y.** No relevant relationships. **P.J.** Payment for lectures from World Class CME. **L.C.** No relevant relationships. **S.R.** Royalties from Elsevier. **R.M.K.** Payment for lectures from Sumitomo Pharmacy (formerly Myovant/Pfizer). **M.M.H.** Payment for lectures from Clinical Educational Symposia—Ultrasound Course; leadership or fiduciary role of Ultrasound for *RadioGraphics*; spouse is employee of Bristol Meyers Squibb. **P.G.** Payment for chapter on fetal musculoskeletal disorder from UpToDate. **M.F.** No relevant relationships. **Y.G.** Book royalties from Elsevier; consultant for Femasys; honoraria from World Class CME; vice-president of the AIUM and chair of the Gynecology section. **Z.K.** No relevant relationships. **S.L.Y.** Grants from the Eunice Kennedy Shriver National Institute of Child Health and Human Development/National Institutes of Health (P01HD106485, R01HD100329, R44 HD097750); royalties from Cicero Diagnostics; patent issued (Methods And Compositions For Sirt1 Expression As A Marker For Endometriosis And Subfertility. Steven L Young, Bruce A Lessey, Jae-Wook Jeong. U.S. Patent No. 11,474,105; Issued October 18, 2022. UNC Ref. 16-0123; MB Ref. 5470.810); president, Society for Reproductive Endocrinology and Infertility (SREI); board member, American Society for Reproductive Medicine (ASRM); board member, Society for Assisted Reproductive Technology (SART). **L.P.** No relevant relationships. **T.L.B.** No relevant relationships. **E.M.H.** Patents planned, issued, or pending from IHC. **S.E.** Patents planned, issued, or pending from Rutgers/RWJ Medical School. **W.V.B.** Travel and hotel covered to speak at the World Endometriosis Congress, American Association of Gynecological Laparoscopists, and the Society for Women's Health Research; member and cofounder of the Society of Abdominal Radiology Endometriosis Disease-Focused Panel.

References

- Mowers EL, Lim CS, Skinner B, et al. Prevalence of Endometriosis During Abdominal or Laparoscopic Hysterectomy for Chronic Pelvic Pain. *Obstet Gynecol* 2016;127(6):1045–1053.
- Tanbo T, Fedorcsak P. Endometriosis-associated infertility: aspects of pathophysiological mechanisms and treatment options. *Acta Obstet Gynecol Scand* 2017;96(6):659–667.
- International working group of AAGL, ESGE, ESHRE and WES; Tomassetti C, Johnson NP, et al. An International Terminology for Endometriosis, 2021. *J Minim Invasive Gynecol* 2021;28(11):1849–1859.
- Chamié LP. Ultrasound evaluation of deeply infiltrative endometriosis: technique and interpretation. *Abdom Radiol (NY)* 2020;45(6):1648–1658.
- Guerriero S, Ajossa S, Orozco R, et al. Accuracy of transvaginal ultrasound for diagnosis of deep endometriosis in the rectosigmoid: systematic review and meta-analysis. *Ultrasound Obstet Gynecol* 2016;47(3):281–289.
- Young SW, Saphier NB, Dahiya N, et al. Sonographic evaluation of deep endometriosis: protocol for a US radiology practice. *Abdom Radiol (NY)* 2016;41(12):2364–2379.
- Young SW, Grossmann Y, Dahiya N, et al. Sonographer-acquired ultrasound protocol for deep endometriosis. *Abdom Radiol (NY)* 2020;45(6):1659–1669.
- Nnoaham KE, Hummelshoj L, Webster P, et al. Impact of endometriosis on quality of life and work productivity: a multicenter study across ten countries. *Fertil Steril* 2011;96(2):366–373.e8.
- Hadfield R, Mardon H, Barlow D, Kennedy S. Delay in the diagnosis of endometriosis: a survey of women from the USA and the UK. *Hum Reprod* 1996;11(4):878–880.
- Aas-Eng MK, Dauser B, Lieng M, et al. Transvaginal sonography accurately measures lesion-to-anal-verge distance in women with deep endometriosis of the rectosigmoid. *Ultrasound Obstet Gynecol* 2020;56(5):766–772.
- Bartlett DJ, Burkett BJ, Burnett TL, Sheedy SP, Fletcher JG, VanBuren WM. Comparison of routine pelvic US and MR imaging in patients with pathologically confirmed endometriosis. *Abdom Radiol (NY)* 2020;45(6):1670–1679.
- Al-Arnawoot B, Chang S, Duignan S, Kiehl AZ, Leonardi M. CAR Practice Statement on Advanced Pelvic Ultrasound for Endometriosis. *Can Assoc Radiol J* 2023;74(4):643–649.
- Guerriero S, Condous G, van den Bosch T, et al. Systematic approach to sonographic evaluation of the pelvis in women with suspected endometriosis, including terms, definitions and measurements: a consensus opinion from the International Deep Endometriosis Analysis (IDEA) group. *Ultrasound Obstet Gynecol* 2016;48(3):318–332.
- Chen-Dixon K, Uzuner C, Mak J, Condous G. Effectiveness of ultrasound for endometriosis diagnosis. *Curr Opin Obstet Gynecol* 2022;34(5):324–331.
- Becker CM, Bokor A, Heikinheimo O, et al. ESHRE guideline: endometriosis. *Hum Reprod Open* 2022;2022(2):hoac009.
- Abrão MS, Petraglia F, Falcone T, Keckstein J, Osuga Y, Chapron C. Deep endometriosis infiltrating the recto-sigmoid: critical factors to consider before management. *Hum Reprod Update* 2015;21(3):329–339.
- Kondo W, Ribeiro R, Trippia C, Zomer MT. Deep infiltrating endometriosis: anatomical distribution and surgical treatment [in Portuguese]. *Rev Bras Ginecol Obstet* 2012;34(6):278–284.
- Chapron C, Fauconnier A, Vieira M, et al. Anatomical distribution of deeply infiltrating endometriosis: surgical implications and proposition for a classification. *Hum Reprod* 2003;18(1):157–161.
- AIUM Practice Parameter for the Performance of an Ultrasound Examination of the Female Pelvis. *J Ultrasound Med* 2020;39(5):E17–E23.
- Deslandes A, Parange N, Childs JT, Osborne B, Bezak E. Current Status of Transvaginal Ultrasound Accuracy in the Diagnosis of Deep Infiltrating Endometriosis Before Surgery: A Systematic Review of the Literature. *J Ultrasound Med* 2020;39(8):1477–1490.
- Gerges B, Li W, Leonardi M, Mol BW, Condous G. Meta-analysis and systematic review to determine the optimal imaging modality for the detection of uterosacral ligaments/torus uterinus, rectovaginal septum and vaginal deep endometriosis. *Hum Reprod Open* 2021;2021(4):hoab041.
- Xiang Y, Wang G, Zhou L, Wang Q, Yang Q. A systematic review and meta-analysis on transvaginal ultrasonography in the diagnosis of deep invasive endometriosis. *Ann Palliat Med* 2022;11(1):281–290.
- Zhang X, He T, Shen W. Comparison of physical examination, ultrasound techniques and magnetic resonance imaging for the diagnosis of deep infiltrating endometriosis: A systematic review and meta-analysis of diagnostic accuracy studies. *Exp Ther Med* 2020;20(4):3208–3220.
- Gerges B, Li W, Leonardi M, Mol BW, Condous G. Meta-analysis and systematic review to determine the optimal imaging modality for the detection of bladder deep endometriosis. *Eur J Obstet Gynecol Reprod Biol* 2021;261:124–133.
- Guerriero S, Ajossa S, Minguez JA, et al. Accuracy of transvaginal ultrasound for diagnosis of deep endometriosis in uterosacral ligaments, rectovaginal septum, vagina and bladder: systematic review and meta-analysis. *Ultrasound Obstet Gynecol* 2015;46(5):534–545.
- Tian Z, Zhang YC, Sun XH, et al. Accuracy of transvaginal ultrasound and magnetic resonance imaging for diagnosis of deep endometriosis in bladder and ureter: a meta-analysis. *J Obstet Gynaecol* 2022;42(6):2272–2281.
- Guerriero S, Saba L, Pascual MA, et al. Transvaginal ultrasound vs magnetic resonance imaging for diagnosing deep infiltrating endometriosis: systematic review and meta-analysis. *Ultrasound Obstet Gynecol* 2018;51(5):586–595.
- Zhou Y, Su Y, Liu H, Wu H, Xu J, Dong F. Accuracy of transvaginal ultrasound for diagnosis of deep infiltrating endometriosis in the uterosacral ligaments: Systematic review and meta-analysis. *J Gynecol Obstet Hum Reprod* 2021;50(3):101953.
- Gerges B, Li W, Leonardi M, Mol BW, Condous G. Optimal imaging modality for detection of rectosigmoid deep endometriosis: systematic review and meta-analysis. *Ultrasound Obstet Gynecol* 2021;58(2):190–200.
- Pereira AMG, Brizon VSC, Carvas Junior N, et al. Can Enhanced Techniques Improve the Diagnostic Accuracy of Transvaginal Sonography and Magnetic Resonance Imaging for Rectosigmoid Endometriosis? A Systematic Review and Meta-analysis. *J Obstet Gynaecol Can* 2020;42(4):488–499.e4.
- Nisenblat V, Bossuyt PM, Farquhar C, Johnson N, Hull ML. Imaging modalities for the non-invasive diagnosis of endometriosis. *Cochrane Libr* 2016;2(2):CD009591.
- Tong A, VanBuren WM, Chamié L, et al. Recommendations for MRI technique in the evaluation of pelvic endometriosis: consensus statement from the Society of Abdominal Radiology endometriosis disease-focused panel. *Abdom Radiol (NY)* 2020;45(6):1569–1586.
- Young SW, Dahiya N, Yi J, Wasson M, Davitt J, Patel MD. Impact of Uterine Sliding Sign in Routine United States Ultrasound Practice. *J Ultrasound Med* 2021;40(6):1091–1096.
- Hudelist G, Fritzer N, Staettner S, et al. Uterine sliding sign: a simple sonographic predictor for presence of deep infiltrating endometriosis of the rectum. *Ultrasound Obstet Gynecol* 2013;41(6):692–695.
- Rao T, Condous G, Reid S. Ovarian Immobility at Transvaginal Ultrasound: An Important Sonographic Marker for Prediction of Need for Pelvic Sidewall Surgery in Women With Suspected Endometriosis. *J Ultrasound Med* 2022;41(5):1109–1113.

36. Alborzi S, Poordast T, Askary E, et al. Evaluation and comparison of the accuracy of transvaginal ultrasound and MRI for the diagnosis of deep rectal endometriosis: A cross-sectional study. *Int J Gynaecol Obstet* 2023;161(2):586–593.
37. Aas-Eng MK, Montanari E, Lieng M, Keckstein J, Hudelist G. Transvaginal Sonographic Imaging and Associated Techniques for Diagnosis of Ovarian, Deep Endometriosis, and Adenomyosis: A Comprehensive Review. *Semin Reprod Med* 2020;38(2-03):216–226.
38. Exacoustos C, De Felice G, Pizzo A, et al. Isolated Ovarian Endometrioma: A History Between Myth and Reality. *J Minim Invasive Gynecol* 2018;25(5):884–891.
39. Ferrero S, Barra F, Scala C, Condous G. Ultrasonography for bowel endometriosis. *Best Pract Res Clin Obstet Gynaecol* 2021;71:38–50.
40. Levine D, Patel MD, Suh-Burgmann EJ, et al. Simple Adnexal Cysts: SRU Consensus Conference Update on Follow-up and Reporting. *Radiology* 2019;293(2):359–371.
41. Dunselman GA, Vermeulen N, Becker C, et al. ESHRE guideline: management of women with endometriosis. *Hum Reprod* 2014;29(3):400–412.
42. Ballard KD, Seaman HE, de Vries CS, Wright JT. Can symptomatology help in the diagnosis of endometriosis? Findings from a national case-control study—Part 1. *BJOG* 2008;115(11):1382–1391.
43. Chapron C, Souza C, Borghese B, et al. Oral contraceptives and endometriosis: the past use of oral contraceptives for treating severe primary dysmenorrhea is associated with endometriosis, especially deep infiltrating endometriosis. *Hum Reprod* 2011;26(8):2028–2035.
44. Vercellini P, Eskenazi B, Consonni D, et al. Oral contraceptives and risk of endometriosis: a systematic review and meta-analysis. *Hum Reprod Update* 2011;17(2):159–170.
45. American Institute of Ultrasound in Medicine (AIUM); American College of Radiology (ACR); American College of Obstetricians and Gynecologists (ACOG); Society for Pediatric Radiology (SPR); Society of Radiologists in Ultrasound (SRU). AIUM practice guideline for the performance of ultrasound of the female pelvis. *J Ultrasound Med* 2014;33(6):1122–1130.
46. Tammaa A, Fritzer N, Strunk G, Krell A, Salzer H, Hudelist G. Learning curve for the detection of pouch of Douglas obliteration and deep infiltrating endometriosis of the rectum. *Hum Reprod* 2014;29(6):1199–1204.
47. Indrielle-Kelly T, Fischerova D, Hanuš P, et al. Early Learning Curve in the Assessment of Deep Pelvic Endometriosis for Ultrasound and Magnetic Resonance Imaging. *Biomed Res Int* 2020;2020:8757281.
48. Maple S, Chalmers KJ, Bezak E, Henry K, Parange N. Ultrasound Characteristics and Scanning Techniques of Uterosacral Ligaments for the Diagnosis of Endometriosis: A Systematic Review. *J Ultrasound Med* 2023;42(6):1193–1209.
49. Reid S, Lu C, Casikar I, et al. Prediction of pouch of Douglas obliteration in women with suspected endometriosis using a new real-time dynamic transvaginal ultrasound technique: the sliding sign. *Ultrasound Obstet Gynecol* 2013;41(6):685–691.
50. Arion K, Aksoy T, Allaire C, et al. Prediction of Pouch of Douglas Obliteration: Point-of-care Ultrasound Versus Pelvic Examination. *J Minim Invasive Gynecol* 2019;26(5):928–934.
51. Gerges B, Lu C, Reid S, Chou D, Chang T, Condous G. Sonographic evaluation of immobility of normal and endometriotic ovary in detection of deep endometriosis. *Ultrasound Obstet Gynecol* 2017;49(6):793–798.
52. Reid S, Leonardi M, Lu C, Condous G. The association between ultrasound-based 'soft markers' and endometriosis type/location: A prospective observational study. *Eur J Obstet Gynecol Reprod Biol* 2019;234:171–178.
53. Exacoustos C, Malzoni M, Di Giovanni A, et al. Ultrasound mapping system for the surgical management of deep infiltrating endometriosis. *Fertil Steril* 2014;102(1):143–150.e2.
54. Orlando MS, Cadish LA, Shepherd JP, Falcone T, Chang OH, Kho RM. Salpingo-oophorectomy or surveillance for ovarian endometrioma in asymptomatic premenopausal women: a cost-effectiveness analysis. *Am J Obstet Gynecol* 2022;227(2):311.e1–311.e7.
55. Pearce CL, Templeman C, Rossing MA, et al. Association between endometriosis and risk of histological subtypes of ovarian cancer: a pooled analysis of case-control studies. *Lancet Oncol* 2012;13(4):385–394.
56. Saavalainen L, Lassus H, But A, et al. Risk of Gynecologic Cancer According to the Type of Endometriosis. *Obstet Gynecol* 2018;131(6):1095–1102.
57. Vercellini P, Viganò P, Buggio L, et al. Perimenopausal management of ovarian endometriosis and associated cancer risk: When is medical or surgical treatment indicated? *Best Pract Res Clin Obstet Gynaecol* 2018;51:151–168.
58. Andreotti RF, Timmerman D, Benacerraf BR, et al. Ovarian-Adnexal Reporting Lexicon for Ultrasound: A White Paper of the ACR Ovarian-Adnexal Reporting and Data System Committee. *J Am Coll Radiol* 2018;15(10):1415–1429.[Published correction appears in *J Am Coll Radiol* 2019;16(3):403–406.]
59. Strachowski LM, Jha P, Phillips CH, et al. O-RADS US v2022: An Update from the American College of Radiology's Ovarian-Adnexal Reporting and Data System US Committee. *Radiology* 2023;308(3):e230685.
60. Malzoni M, Casarella L, Coppola M, et al. Preoperative Ultrasound Indications Determine Excision Technique for Bowel Surgery for Deep Infiltrating Endometriosis: A Single, High-Volume Center. *J Minim Invasive Gynecol* 2020;27(5):1141–1147.
61. Ros C, de Guirior C, Rius M, et al. Accuracy of Transvaginal Ultrasound Compared to Cystoscopy in the Diagnosis of Bladder Endometriosis Nodules. *J Ultrasound Med* 2021;40(8):1571–1578.
62. Noventa M, Saccardi C, Litta P, et al. Ultrasound techniques in the diagnosis of deep pelvic endometriosis: algorithm based on a systematic review and meta-analysis. *Fertil Steril* 2015;104(2):366–83.e2.
63. Benacerraf BR, Groszmann Y, Hornstein MD, Bromley B. Deep infiltrating endometriosis of the bowel wall: the comet sign. *J Ultrasound Med* 2015;34(3):537–542.
64. Ghezzi F, Raio L, Cromi A, et al. "Kissing ovaries": a sonographic sign of moderate to severe endometriosis. *Fertil Steril* 2005;83(1):143–147.
65. Di Donato N, Montanari G, Benfenati A, et al. Prevalence of adenomyosis in women undergoing surgery for endometriosis. *Eur J Obstet Gynecol Reprod Biol* 2014;181:289–293.
66. Olgan S, Dirican EK, Ozsipahi AC, Sakinci M. Uterine involvement by endometriosis: Sonographic features from elusive findings to apparent adenomyosis. *Eur J Obstet Gynecol Reprod Biol* 2021;262:93–98.
67. Harmsen MJ, Van den Bosch T, de Leeuw RA, et al. Consensus on revised definitions of Morphological Uterus Sonographic Assessment (MUSA) features of adenomyosis: results of modified Delphi procedure. *Ultrasound Obstet Gynecol* 2022;60(1):118–131.
68. Van den Bosch T, Dueholm M, Leone FP, et al. Terms, definitions and measurements to describe sonographic features of myometrium and uterine masses: a consensus opinion from the Morphological Uterus Sonographic Assessment (MUSA) group. *Ultrasound Obstet Gynecol* 2015;46(3):284–298.
69. Patel MD, Acord DL, Young SW. Likelihood ratio of sonographic findings in discriminating hydrosalpinx from other adnexal masses. *AJR Am J Roentgenol* 2006;186(4):1033–1038.
70. Bazot M, Bharwani N, Huchon C, et al. European society of urogenital radiology (ESUR) guidelines: MR imaging of pelvic endometriosis. *Eur Radiol* 2017;27(7):2765–2775.
71. Goncalves MO, Siufi Neto J, Andres MP, Siufi D, de Mattos LA, Abrao MS. Systematic evaluation of endometriosis by transvaginal ultrasound can accurately replace diagnostic laparoscopy, mainly for deep and ovarian endometriosis. *Hum Reprod* 2021;36(6):1492–1500.
72. Mattos LA, Goncalves MO, Andres MP, et al. Structured Ultrasound and Magnetic Resonance Imaging Reports for Patients with Suspected Endometriosis: Guide for Imagers and Clinicians. *J Minim Invasive Gynecol* 2019;26(6):1016–1025.
73. Guerriero S, Pascual MA, Ajossa S, et al. Learning curve for ultrasonographic diagnosis of deep infiltrating endometriosis using structured offline training program. *Ultrasound Obstet Gynecol* 2019;54(2):262–269.
74. Young SW, Dahiya N, Patel MD, et al. Initial Accuracy of and Learning Curve for Transvaginal Ultrasound with Bowel Preparation for Deep Endometriosis in a US Tertiary Care Center. *J Minim Invasive Gynecol* 2017;24(7):1170–1176.
75. Leonardi M, Reid S, Lu C, et al. Diagnostic Accuracy and Reproducibility of Predicting Cul-de-Sac Obliteration by General Gynaecologists and Minimally Invasive Gynaecologic Surgeons. *J Obstet Gynaecol Can* 2019;41(4):443–449.e2.
76. Nisenblat V, Prentice L, Bossuyt PM, Farquhar C, Hull ML, Johnson N. Combination of the non-invasive tests for the diagnosis of endometriosis. *Cochrane Libr* 2016;7(7):CD012281.
77. Chapron C, Tosti C, Marcellin L, et al. Relationship between the magnetic resonance imaging appearance of adenomyosis and endometriosis phenotypes. *Hum Reprod* 2017;32(7):1393–1401.
78. Reid S, Condous G. Update on the ultrasound diagnosis of deep pelvic endometriosis. *Eur J Obstet Gynecol Reprod Biol* 2017;209:50–54.
79. Indrielle-Kelly T, Frühauf F, Burgetová A, Fanta M, Fischerová D. Diagnosis of endometriosis 2nd part - Ultrasound diagnosis of endometriosis

- (adenomyosis, endometriomas, adhesions) in the community. *Ceska Gynekol* 2019;84(4):260–268.
80. Zannoni L, Ambrosio M, Raimondo D, et al. Question Mark Sign and Transvaginal Ultrasound Uterine Tenderness for the Diagnosis of Adenomyosis: A Prospective Validation. *J Ultrasound Med* 2020;39(7):1405–1412.
 81. Reid S, Lu C, Condous G. Can we improve the prediction of pouch of Douglas obliteration in women with suspected endometriosis using ultrasound-based models? A multicenter prospective observational study. *Acta Obstet Gynecol Scand* 2015;94(12):1297–1306.
 82. Manieri Rocha R, Leonardi M, Eathorne A, Armour M, Condous G. Anatomical distribution of endometriosis: A cross-sectional analysis of transvaginal ultrasound in symptomatic patients. *Australas J Ultrasound Med* 2023;26(3):131–141.
 83. Kobayashi H, Matsubara S, Imanaka S. Clinicopathological features of different subtypes in adenomyosis: Focus on early lesions. *PLoS One* 2021;16(7):e0254147.
 84. Qi H, Zhang H, Zhang D, et al. Reassessment of prevalence of tubal endometriosis, and its associated clinicopathologic features and risk factors in premenopausal women received salpingectomy. *Eur J Obstet Gynecol Reprod Biol X* 2019;4:100074.